

## OSSEOUS REPAIR OF THE FRACTURED MANDIBULAR CONDYLE IN CHILDREN

Chang-Seo Park · Kwang-Ok Bong\*

*Department of Dental Radiology, Dental College of Dentistry,  
Yonsei University, Seoul, Korea*

*\*Department of Radiology, Nippon Dental College,  
Tokyo, Japan*

### - CONTENTS -

- I. INTRODUCTION
- II. MATERIALS and METHODS
- III. RESULTS
- IV. DISCUSSION
- V. CONCLUSION
- VI. REFERENCES
- VII. ABSTRACT

### I. INTRODUCTION

Fractures of the condyle account for between 25% and 35% of all mandibular fractures in reported series.<sup>1</sup> Hall et al.<sup>2</sup> reviewed 2194 maxillofacial injuries and 983 fractures of the facial bones were sustained, of which 242(24.6%) occurred in the mandible. 98(40.5%) of the mandibular fractures affected the condyle, 22(22.4%) of which were located in the condylar head and 76(77.6%) were subcondylar fractures.

Final diagnosis of condylar fractures depends on proper clinical and radiologic findings. MacLenann<sup>3</sup> made the simple and practical classification of condylar fracture patterns and he divided

**Table 1.** Patient Lists

Patient Name	Age in Years	Sex	Fracture Site	Clinical Findings	Radiologic Findings	Follow-up Period
1.KTG	4 7/12	M	Rt	D,S,T	Dislocation	2 Yrs.
2.LSG	3 3/12	M	Rt	D,S,T	Dislocation	2 Yrs 1 Mos.
3.KDC	2 8/12	M	Bilat	LOM,S,T	Displacement Displacement	5 Mos.
4.JGT	4	M	Lt	LOM,T		1 Mos.
5.KSH	5	F	Lt	D,LOM	Displacement	7 Mos.
6.JEJ	2	F	Rt	T	Dislocation	5 Mos.
7.CBG	3	M	Bilat	T	No Displacement Displacement	2 Mos.
8.PSN	7	F	Rt	D,T	Displacement	5 Yrs.
9.KHY	7 10/12	F	Bilat	LOM,T	Dislocation	2 Mos.
10.PGS	8 2/12	M	Bilat	D,LOM	Displacement Displacement	8 Mos.
11.JYS	4	M	Rt	S,T	Dislocation	2 Yrs 2 Mos.
12.JDG	3	M	Bilat	S,T	No Displacement	2 Yrs.
13.CJH	7 10/12	M	Bilat	M,S,T	Displacement Dislocation	2 Yrs.

D : Deviation of Mandibular Midline

LOM : Limitation of Mouth Opening

M : Malocclusion

S : Swelling

T : Tenderness

Rt : Right

Lt : Left

Bilat : Bilateral

his classification into four main categories. The terms no displacement, fracture deviation, fracture displacement and fracture dislocation are used.

The topic of condylar injury has generated more discussion and controversy than any other in the field of maxillofacial trauma, because the basic mechanisms of repair of the condyle after injury have not been fully appreciated. This has resulted in the evolution of three principal schools of treatment, namely, conservative, relying on rest and immobilisation; functional, where the accent is on active movement as an aid to restitution; and surgical, where operative reduction is the objective.<sup>1</sup> There is the fundamentally different repair potential between the adult, where remodeling after fracture is confined to an adjusting role, and the child, where restitutional changes of a very major degree can occur.<sup>1</sup> Condylar fractures in children, not associated with other fractures of the mandible, constitute a unique situation. This is, perhaps, the only skeletal fracture in which no attempt to regain anatomic reduction is necessary.

The purpose of this study is to evaluate radiologically the healing process that can take place in the fractured mandibular condyles of the growing children.

## II. MATERIALS and METHODS

This study was based on the thirteen cases of patients attending the Dental Hospital of Yonsei University between 1987 and 1991 for whom complete records were available. Patient's cases with

a follow-up of over 1 month after accident, and the age is below 12 years old were evaluated. The preoperative radiologic examination of all patients consisted of a panoramic radiograph and tomograms of temporomandibular joint. Clinical and radiologic findings were listed according to the patient ages and fracture site in Table 1. Fractures varied from greenstick with no displacement, to severely displaced fractures with anteromedial angulation of the condylar neck.

The clinical findings at the first examination in the hospital commonly included tenderness and swelling over the temporomandibular joints in varying degrees. Often there was trismus secondary to guarding. Those with bilateral fractures had an open bite. Molar relationships were difficult to evaluate initially. In each instance the diagnosis was confirmed radiographically. As the swelling decreased over the first week, occlusal relationships could be ascertained. The patients were able then to occlude their teeth and the range of motion increased. For a weeks following the trauma there was often deviation to the side of the fracture on wide mouth opening.

### III. RESULTS

All fractures were treated by nonsurgical conservative or functional regime. The aims of these treatments are to encourage active movement of the jaw as early as possible provided that the patient can bring the teeth into the normal occlusion. Persistent failure to achieve normal occlusion should require a unilateral fracture to be immobilized for 7-10 days, and bilateral fractures for 21 days.

Two patients had a marked clicking sounds on the affected joints in maximal opening, but no other disturbances or symptoms of dysfunction were evident. In the other patients, normal function and guidance of the jaw were obtained, despite radiologic findings of remodeling along with modest changes of the articular surface of the condyle.

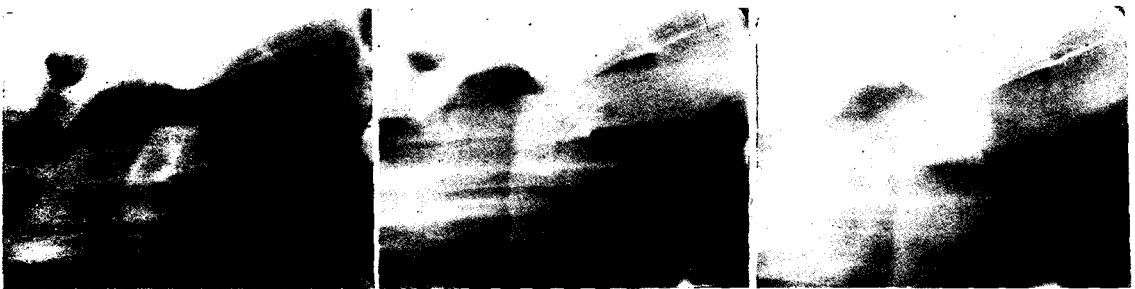Radiographic changes observed following the fracture reveal a morphologic variation of condyle by remodeling (Figs. 1,2,3 and 4). Fortunately, cases in which the displaced or dislocated condylar process is inclined in an upside-down position of more than 90° are rare.





Fig.1. Serial panoramic radiographs showing unilateral fracture dislocation of right mandibular condyle in a 4 <sup>7</sup>/<sub>12</sub>-year-old boy. (Left) The upper fragment displaced inferiorly. (Middle) Two months later, bony union by remodeling was noted. (Right) Two years later, a new condyle apparently had formed and the child had a full range of mandibular function.



**Fig. 2.** Serial tomograms showing unilateral fracture dislocation of right mandibular condyles in the same patient of Fig.1. case. (Left) One month later, there was evidence of a new condyle forming, but fractured condylar fragment was not noted clearly. (Middle) Four months later, the remodeling and new bone forming were noted. (Right) Two years later, the new condyle had a smooth contouring of condylar surface.



**Fig.3.** Serial panoramic radiographs showing unilateral fracture dislocation of right mandibular condyle in a 3 <sup>3</sup>/<sub>12</sub>-year-old boy. (Left) The upper fragment displaced inferiorly. (Middle) Five months later, the condylar head become abbreviated by bony union and remodeling. (Right) Two years and two months later, bony union was accompanied by remodeling and abnormal positioning of condylar head. Occlusion was good after injury, and the only clinical finding was clicking sounds in the affected temporomandibular joint.



**Fig. 4.** Serial tomograms showing unilateral fracture dislocation of right mandibular condyles in the same patient of Fig.3. case. (Left) The upper fragment badly displaced inward. (Middle) Two months later, the new bone on the medial aspect of the condylar neck has become approximated to the new bone forming on the surface of the condylar neck. (Right) 2 years 1 month later, the width of condylar neck had become thickened as the fracture gap has filled with new bone.

#### IV. DISCUSSION

In examining the patient with a suspected injury of the condylar region, one should pay special attention to the clinical and radiologic features. A post-traumatic effusion or haemarthrosis may distract the joint surfaces, causing a posterior open bite on the affected side with deviation of the mandibular mid-line to the opposite side.<sup>1</sup> A unilateral fracture with dislocation or significant displacement may result in telescoping of the fragments under the action of the pterygo-masseteric sling with ipsilateral premature posterior dental contact and deviation of the mandibular midline to the affected side.<sup>1</sup> Bilateral fracture dislocation will cause premature posterior contact on both side with no deviation of the midline and an anterior open bite.<sup>1</sup>

The pattern of fractures with condylar displacement and dislocation is related to the anatomic structure of the fossa and the configuration of the condylar process.<sup>4</sup> The angle of the fossa along the skull base, the relatively thick lateral cortex of the condylar neck compared with the medial cortex, and the broad elliptical shape of the condyle explain the fact that in our cases the luxated condyle was dislocated medially out of the fossa and beneath the skull base (Fig 1,2,3 and 4.) Lateral displacement of the condyle was never seen.

During the ages from birth to the age of about 12 years, the face is in a period of almost continuous growth. Cephalometric studies divide the growth of jaws and facial bones into rapid and slow growth periods.<sup>5,6</sup> An injury incurred and treated during a period of slow growth will have a lesser deformity potential than an injury incurred and treated during a rapid growth period. The clinicians who treats these injuries should have a thorough knowledge of facial development.<sup>7</sup> In the child, rapid union can be expected due to the high osteogenic potential of the periosteum, increased metabolic rate, and a very excellent blood supply. The child has very rapid callus formation.<sup>6,8,9,10,11,12</sup> During the first three years of life, the condyle consists of a delicate vascular sponge covered by thin bone. Its ability to absorb frontal trauma along the long axis of the condyle neck without distortion or fracture is low. The potential for haemarthrosis, intracapsular hemorrhage and ankylosis of the fragments to the bone of the glenoid fossa is high. These fractures of the high intracapsular type are complicated because of the intracapsular hemorrhage and their response for ankylosis. Fractures of this type are treated by early mobilization, aspiration, enzymes, and intra-articular steroids.<sup>7</sup> As far as disturbance of mandibular growth is concerned, the role of the condylar cartilage in development has recently been reviewed in the light of the 'functional matrix' theory of facial development. Here it is no longer regarded as 'the mandibular growth centre' with an active and dominant role in the downward and forward development of the lower jaw, but rather as a site of passive response in the form of secondary adaptation.<sup>13,14</sup> Condylar fractures in children, not associated with other fractures of the mandible, constitute a unique situation. This is, perhaps, the only skeletal fracture in which no attempt to regain anatomic reduction is necessary.<sup>15</sup>

In our patients, a conservative immobilisation regime by intermaxillary fixation can be undertaken in eight patients, and functional active mobilisation regime was undertaken in five patients. In our patients under the age of 12 years bony union and adaptive remodelling will restore a functional condyle regardless of treatment in the majority of subjects. Minor disturbance in occlusion such as a slight degree of persistent premature posterior contact in a unilateral fracture

dislocation can be accepted in the knowledge that this will almost certainly settle spontaneously, or that any slight residual defect will be rapidly corrected by further eruption of existing teeth, particularly the premolars. Significant occlusal disharmony may be seen after bilateral fracture dislocation with open bite and possible retro-positioning of the mandible. In such cases malunion could result in a deficit too great for compensation. Treatment in these circumstances should, as in the case of an adult, be by a conservative immobilisation regime. A persistent failure to achieve a normal occlusion by the principles already stated may require a unilateral fracture to be immobilised for 10-14 days. However, a bilateral fracture will need 3 weeks in a child. Rigid osteosynthesis of the fracture is, in our opinion, contraindicated. Even a relatively minimal aberration of the configuration of the condyle in comparison to the original one will often lead to resorption and dysfunction along with involvement of the contralateral joint. For this reason, such fractures, once repositioned, are treated by us with intermaxillary fixation for only ten days and consequent intensive physiotherapy for 3 to 4 weeks so as to enable a correct functional adaptation of the condyle to the fossa. Even if significant displacement of the fracture is present, the treatment is nonsurgical as long as the condyle is in the fossa<sup>16</sup>. (Raveh 89) The clinician is aided in his treatment technique by the favorable factor of the jaws. Wolf's law is well known. With function it has been noted that bone will recontour as a result of stress placed upon it.<sup>17,18,19</sup> Appropriate functional appliances involving alveolar bone, masticatory muscles, and teeth may guide the patient into a functional occlusion and aid in a favorable growth results.<sup>20,21</sup> Some surgeons reserve the open reduction procedures for condylar fractures in children, whereas others advocate extreme caution and conservative treatment of fractures of the condylar process in young patients.<sup>22,23</sup> Still other surgeons<sup>22,24</sup> have disagreed with the concept of open reduction treatment for condylar fractures occurring in either children or adults. It is pointed out by the advocates of the closed reduction approach that radiographic evidence of remodeling and "sculpturing" of the fractured-displaced mandibular condyle has been demonstrated consistently after conservative treatment consisting merely of intermaxillary immobilization.<sup>24</sup>

One of the problems in evaluating treatment results is that there have been few long-term surveys of fractured condyles in the majority of our cases, and only a very small number of cases were selected.

## V. CONCLUSION

In our series, there were good results from the treatment of condylar fractures by "conservative or functional approach", and regeneration and remodeling of bone is rapid and seems to be in confirmity with Wolff's law that bone responds to the stress placed on it during function. Two cases of fracture dislocation had shown abbreviated changes of condylar head and clicking sounds on the affected joints, but had no difficulty in eating and opening the jaw. The results have been gratifying in the majority of all cases, although a shorter follow-up would be insufficient.

## VI. REFERENCES

1. Bradley P. Injuries of the condylar and coronoid process. *Maxillofacial Injuries* 1985; 1: 337-62.
2. Hall RK, Thomas G, Buzowski G. Ten year survey of traumatic injuries to the face and jaws of children

- 1970-1979:a computer analysis. *Paper presented at the Eighth International Conference on Oral Surgery*; Berlin, 1983.
3. MacLennan WD. Consideration of 180 cases of typical fractures of the mandibular condylar process. *British Journal of Plastic Surgery* 1952; 5: 122.
  4. Raveh J, Vuillemin T, Ladrach K. Open reduction of the dislocated, fractured condylar process : Indications and surgical procedures. *J Oral Maxillofac Surg* 1989; 47: 120-6.
  5. Hale ML. The diagnosis and management of pediatric jaw fractures. *J Iowa Med Soc* 1968; 58: 1227.
  6. Hale ML. *Textbook of Practical Oral Surgery*. Philadelphia: Lea and Febiger, 1972: 423-7.
  7. Waite DE. Pediatric fractures of jaw and facial bones. *Pediatrics* 1973; 51: 551-9.
  8. Kazanjian VH, Converse JM. *The surgical treatment of facial injury ed 2*. Williams & Wilkins Co.: Baltimore, 1959: 137-141.
  9. Georgiade NG, Pickrell KL. Treatment of maxillofacial injuries in children. *J Int Coll Surg* 1957; 27: 640.
  10. Freid MG, Baden E. Management of fractures in children. *J Oral Surg* 1954; 12: 129.
  11. Khosl VM, Boren W. Mandibular fractures in children and their management. *J Oral Surg* 1971; 29: 116.
  12. Graham GG, Peletier JR. Management of mandibular fractures in children. *J Oral Surg* 1960; 18: 416.
  13. Poswillo D. Experimental reconstruction of the temporomandibular joint. *International Journal of Oral Surgery* 1974; 3: 400.
  14. Rowe NL. Ankylosis of the temporomandibular joint. *Journal of the Royal College of Surgeons of Edinburgh* 1982; 67: 167-209.
  15. Gordon S. Interosseous wiring in the treatment of fractures of the mandible. *Arch Surg* 1947; 55: 660.
  16. Raveh j, vuillemin T, Ladrach K. Open reduction of the dislocated, fractured condylar process: indication and surgicalo procedures. *J Oral Maxillofac Surg* 1989; 47: 120-6.
  17. Rakower W, Protzell A, Rosencrans M. Treatment of displaced condylar fractures in children. *J Oral Surg* 1961; 19: 517.
  18. Kaplan SI, Mark HI. Bilateral fractures of the mandibular condyle and fracture of the symphysis menti in an 18-month-old child. *Oral Surg* 1962; 15: 136.
  19. Blevins C, Gores RJ. Fractures of the mandibular condyloid process: results of conservative treatment of 140 patients. *J Oral Surg* 1961; 19: 392.
  20. Cocco PJ. Restitution of mandibular form after condylar injury in infancy (a 7-year study of a child.) *Amer J Orthodont* 1969; 55: 32-49.
  21. Folke LEA, Stallard RE. Condylar adaptation to changes in intermaxillary relationship. *J Periodont Res* 1966; 1: 79.
  22. Graham GG, Peltier JR. Management of mandibular fractures in children. *J Oral Surg Anesth Hosp Dent Serv* 1960; 18: 416.
  23. Caldwell JB. The consultant. *Oral Surg Anesth Hosp Dent Serv* 1964; 22: 460.
  24. Eubanks RJ. Fractures of the neck of the condyloid process. *J Oral Surg* 1964; 22: 285-91.

## 소아에서 발생한 골절된 하악과두의 골회복

박창서 · 봉광옥\*

연세대학교 치과대학 치과방사선학 교실  
일본치과대학 방사선학 교실\*

본 연구는 1987년 1월부터 1991년 12월까지 연세대학교치과병원 구강악안면외과에 과두 골절이 의심되어 내원한 환자중 임상 및 방사선학적 소견에서 하악과두 골절로 진단되어 비외과적 치료를 받은 12세 미만의 13명의 소아환자를 연구 대상으로 하여 임상 및 방사선학적 소견을 분석하여 다음과 같은 결론을 얻었다.

비외과적인 보존적 또는 기능적 치료를 받은 후의 결과는 양호하였으며, 골의 재생과 개조는 신속하여 골 구조는 기능 중에 가해진 힘에 반응한다는 Wolff의 법칙과 일치하는 듯이 보였다. 두 예의 골절탈구에서 과두의 단축 및 과두가 골절된 악관절에서 clicking음을 보였으나 저작하거나 개구시에 큰 어려움은 없었다. 술후 관찰기간이 불충분하였으나 본 예의 대부분에서 비외과적인 술식에도 만족스러운 치료결과를 보였다.