

## Postoperative Evaluation of Funnel Chest — The role of radiologic indices —

T.J. Yun, M.D.\*, S.W. Sung, M.D.\*, K.B. Kim, M.D.\*, J.H. Kim, M.D.\*

### — Abstract —

There are many objective indices of operative outcome of funnel chest, but there has been only a few report about the postoperative change of these indices and which is best correlated with subjective outcome. From January 1989 to December 1991, 74 patients with funnel chest underwent Ravitch operation and radiologic evaluation was performed on the twenty patients whose operative outcome were satisfactory by Humphreys' criteria and postoperative chest x-ray were available. Variable radiologic chest indices such as deformity grade (DG), lower vertebral index (LVI), upper vertebral index (UVI) and configuration index (CI) were measured preoperatively and 1, 6, 12 and 18 months postoperatively. The mean value of preoperative DG, LVI, UVI and CI were 5.32, 0.3, 0.26 and 1.01 respectively, and postoperative changes were as follows ; DG : 3.13, 3.66, 3.72, 4.0, LVI : 0.22, 0.24, 0.25, 0.25 UVI : 0.27, 0.27, 0.27, 0.27 CI : 0.69, 0.77, 0.76, 0.79. The increments of CI were within the 90 percent confidence limit of normogram in most cases, but it was not true for LVI and UVI. And the differences between the observed and expected values of CI did not change significantly through the postoperative periods, which was not the case in LVI. We concluded from these results that 1) DG, LVI and CI were increased slowly during the postoperative follow up periods but the increments of CI were usually within the normal limits and so 2) CI can be used as a objective index of satisfactory outcome.

There are many indices for the assessment of the severity of the funnel chest ; vertebral indices<sup>1)</sup>, deformity grade and Welch index<sup>6)</sup>, pectus index using computerized tomography<sup>7,8)</sup>, funnel chest index by external chest wall measurement<sup>9)</sup>, Moire phototopography<sup>10)</sup> and so forth. But the lack of standardized method of measuring and recording the severity of the deformity make it difficult to evaluate postoperative outcome as well as preoperative assessment. Although Humphreys classification has been widely accepted and used, it is not objective but subjective index and bod-

erline cases may ensue : satisfactory or not. We should have objective index above certain level of which we can say the operative outcome is satisfactory, which is easily measurable without special equipments, and which is well correlated with subjective outcome. We selected some patients of satisfactory subjective outcome and measured depression ratio (DR), deformity grade (DG), Welch index (WI), lower vertebral index (LVI), upper vertebral index (UVI) and configuration index (CI) before and 1,6,12,18 months after operation, and compare the observed values of LVI, UVI and CI with the normogram in function of age taken from 250 healthy persons<sup>11)</sup>. If there is

\*Department of Thoracic and Cardiovascular Surgery,  
College of Medicine, Seoul National University

no significant difference between the observed and expected values, we can use the normogram as a objective index for the satisfactory operative outcome.

### Patients and methods

From January 1989 to December 1991, 74 patients of funnel chest deformity, 55 males and 19 females, underwent Ravitch operation. Twenty patients, 13 male and 7 female, were selected from these patients according to the following criteria :

- 1) optimal age for operation (3 to 9 years old)<sup>2,3,4)</sup>
- 2) symmetric deformity and no vertebral or other associated anomaly
- 3) satisfactory subjective outcome on Humphreys classification and no postoperative complication
- 4) serial postoperative chest x-ray films available.

Their mean age was 53 months, ranging from 24 to 107 months, and operative outcomes were all satisfactory (excellent ; 11, good ; 9). Various radiologic indices above mentioned (Figure 1,2) were measured before and 1,6,12 and 18 months after operation and compared with the normal values calculated from following functions taken from 250 healthy persons (Figure 3,4,5)<sup>1)</sup> :

$$LVI = 0.193(1 - 0.036 \times e^{-0.258 \times \text{age}}) \pm 0.038$$

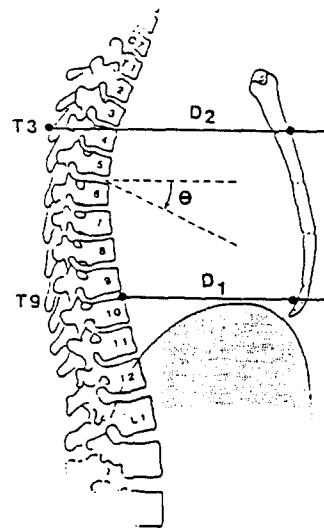
$$UVI = 0.192 \pm 0.038$$

$$CI = 0.7004 + 0.0091 \times \text{age} \pm 0.105$$

(The range designates 90% confidence limits)

The increased value of the UVI or LVI means a narrowing of the chest at that level, and an increased value of the CI implies that the narrowing is more pronounced at the lower end of the chest, and vice versa.

Humphreys classification<sup>5)</sup> ; Results were termed "excellent" when there was no depression or obvious scar, and the symptoms, if any, had gone. When there was some residual or recurrent sternal depression or if the scar was bothersome, but in general the patient and family were satisfied, the result termed "good." Taken together, excellent



$$\text{Depression Ratio (DR)} = D_2 / D_1$$

$$\text{Deformity Grade (DG)} = (1 - \text{DR}) \times 10$$

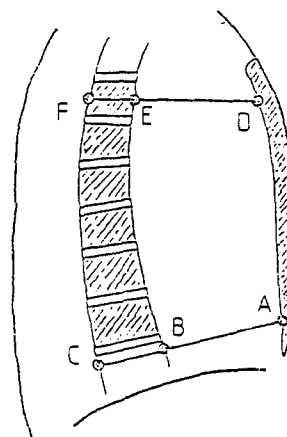
$$\text{Welch index} = \text{DG} + \dots$$

$$0.5 \text{ if Rib Angle } (\theta) > 25^\circ$$

$$\text{and/or}$$

$$0.5 \text{ if Cardiothoracic Ratio} > 50\%$$

**Fig. 1.** Measurement of Deformity Ratio(DR), Deformity Grade(DG) Welch Index(WI)

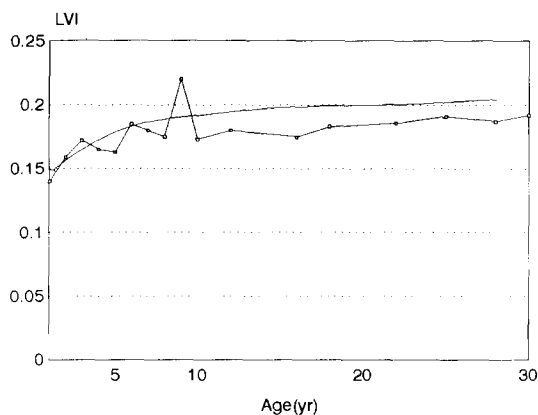


$$\text{UVI (Upper vertebral index)} = EF / DF$$

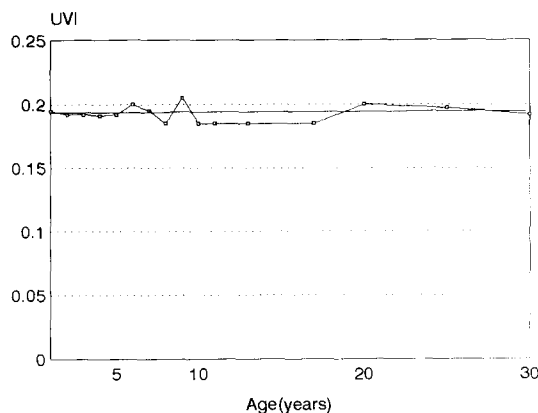
$$\text{LVI (lower vertebral index)} = BC / AC$$

$$\text{CI (Configuration index)} = DE / AB$$

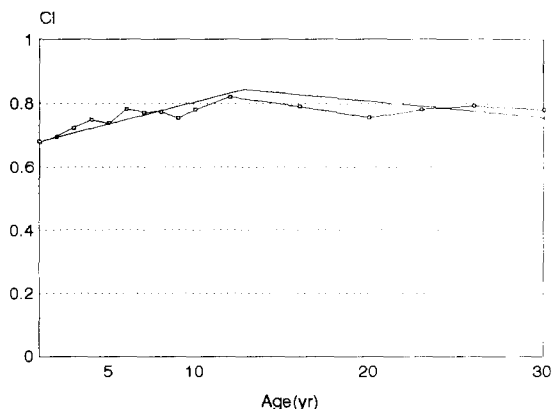
**Fig. 2.** Measurement of Lower Vertebral Index (LVI), Upper Vertebral Index(UVI) Configuration Index(CI)



**Fig. 3.** Normogram of Lower Vertebral Index in function of age (Years)



**Fig. 4.** Normogram of Upper Vertebral Index in function of age (years)



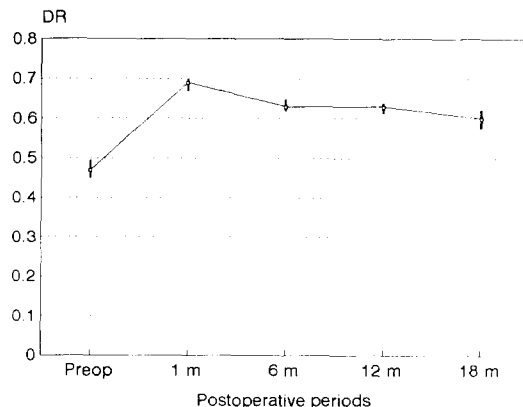
**Fig. 5.** Normogram of Configuration Index in function of age (years)

and good results were considered "satisfactory." In patients with unsightly scar, severe depression or asymmetry, but whose sternum was in better position than preoperative status, the result was termed "fair". If the reoperation should be considered, the result was termed "poor". Fair and poor result were considered "unsatisfactory."

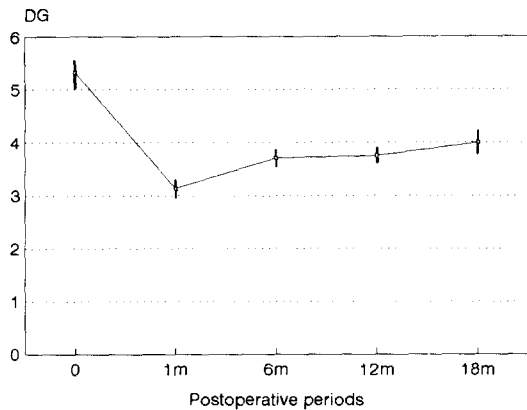
Statistical analysis : Mean with standard error were calculated. The percentage of patients whose indices (LVI, UVI, CI) were within the 90% confidence limit of normal values were also presented. Paired t test was performed between the difference in observed and expected values of one period and that of another. The results were considered to be statistically significant if p values were less than 0.05. SAS (Strategic application software) program was used for the statistical analysis.

## Results

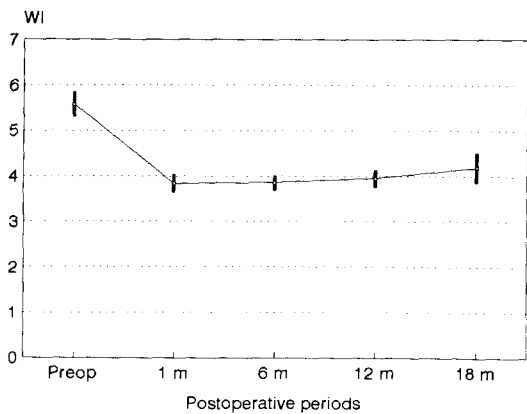
The changes of mean values of DR, DG and WI with their standard error are presented in figure 6, 7, 8. The mean preoperative values are 0.47, 5.32 and 5.58 respectively and the postoperative changes are as follows : DR : 0.69, 0.63, 0.62, 0.60, DG : 3.12, 3.70, 3.75, 4.00 WI : 3.84, 3.86, 3.95, 4.18.



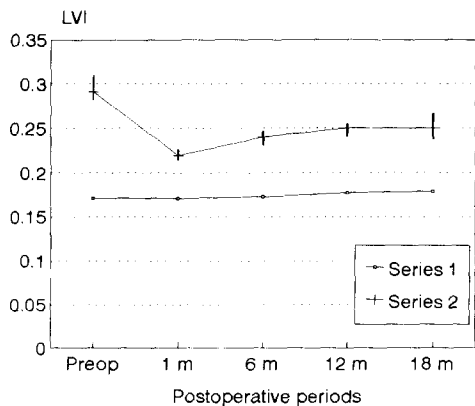
**Fig. 6.** Postoperative Deformity Ratio with Standard error



**Fig. 7.** Postoperative Deformity Grade with standard error

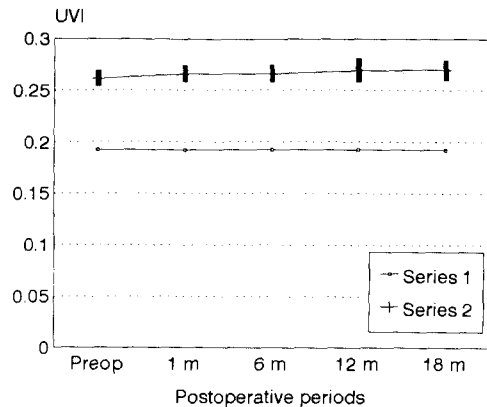


**Fig. 8.** Postoperative Welch Index with standard error

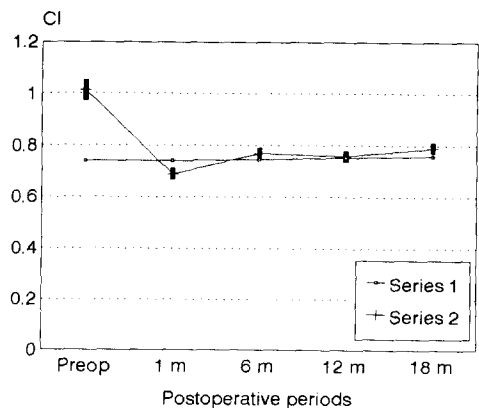


**Fig. 9.** Observed and expected values of lower vertebral index  
series 1 : expected LVI  
series 2 : observed LVI with standard error

The observed LVI, UVI, CI with standard error and comparison between observed and expected values of LVI, UVI and CI are presented in figure 9, 10, 11. The mean preoperative values are 0.30, 0.26, 1.01 respectively and the postoperative changes are as follows : LVI : 0.22, 0.24, 0.25, 0.25, UVI : 0.26, 0.27, 0.27, 0.27, 0.27. CI : 0.69, 0.77, 0.76, 0.79. As the figures show, DG, WI, LVI and CI increased slowly in the postoperative periods while DR decreased and UVI had no change. The mean values of observed LVI and CI were higher than their expected values, and the proportion of



**Fig. 10.** Observed and expected values of UVI  
series 1 : expected UVI  
series 2 : Observed UVI with standard error



**Fig. 11.** Observed and expected values of configuration index  
series 1 : expected CI  
series 2 : observed CI with standard error

**Table 1.** Proportion of patients whose observed LVI, UVI and CI were within the 90% confidence limits of normal values

|     | Preop | Postop 1m | Postop 6m | Postop 12m | Postop 18m |
|-----|-------|-----------|-----------|------------|------------|
| LVI | 0%    | 42%       | 35%       | 8%         | 0%         |
| UVI | 15%   | 15%       | 15%       | 30%        | 13%        |
| CI  | 16%   | 89%       | 80%       | 85%        | 88%        |

patients whose observed LVI, UVI and CI were within the 90% confidence limits of normal values are in table 1. As the table indicates, most of observed CI were within the 90% confidence limits of normal values in postoperative periods while only a part of observed LVI and UVI were within that limits. The results of paired t test between the difference in observed and expected values of one period and that of another are presented in table 2. The increments of observed CI in postoperative periods were not significantly larger than those of expected CI, that was not true in the case of LVI.

**Table 2.** mean, SD(standard deviation) and p values of paired t test for differences of observed and expected values. O means preoperative and 1, 6, 12, 18 mean postoperative 1, 6, 12 and 18 months respectively.

|            | Mean  | SD    | p value |
|------------|-------|-------|---------|
| CI(0, 1)   | 0.267 | 0.177 | 0.0001  |
| CI(1, 6)   | 0.019 | 0.150 | 0.5711  |
| CI(1, 12)  | 0.023 | 0.124 | 0.5012  |
| CI(1, 18)  | 0.013 | 0.217 | 0.8619  |
| LVI(1, 6)  | 0.081 | 0.058 | 0.0001  |
| LVI(1, 6)  | 0.017 | 0.029 | 0.0178  |
| LVI(1, 12) | 0.018 | 0.022 | 0.0103  |
| LVI(1, 18) | 0.024 | 0.040 | 0.1256  |

## Discussion

There are many indices for the assessment of the severity of funnel chest : vertebral indices<sup>1)</sup>, deformity grade and Welch index<sup>6)</sup>, pectus index using computerized tomography<sup>7,8)</sup>, funnel chest index by external chest wall measurement<sup>9)</sup>, Moire

phototopography<sup>10)</sup> and so forth. But the lack of standardized method of measuring and recording the severity of the deformity make it difficult to evaluate data concerning postoperative outcome as well as preoperative evaluation. Although Humphreys classification has been widely accepted and used, it is not objective but subjective index and borderline cases may ensue : satisfactory or not. We should have objective index above certain level of which we can say the operative outcome is satisfactory, which is easily measurable without special equipments, and which is well correlated with subjective outcome. We can measure various indices very accurately using computerized tomography, and these indices can also be used as a effective tools for postoperative evaluation. But we think it is unwise to perform CT scan serially in postoperative periods for all postoperative patients if we consider cost-benefit relation. So we chose deformity grade and vertebral indices proposed by Welch and Derveaux respectively because they could be conveniently measured from lateral chest film and normograms were available in the latter. Deformity grade and Welch index have similar meanings to configuration index but there are two weak points on application ; 1) The lack of normogram and 2) Inappropriate consideration of 5th rib inclination and cardiothoracic ratio in Welch index. The 5th rib inclinations were not corrected, or lowered, even if the sternum were fully elevated in most cases, and cardiothoracic ratio of immediate postoperative periods were usually more than 50%, which may falsely elevate the score. Upper vertebral index is usually higher than normal in funnel chest and

remains unchanged postoperatively because sternal elevation is performed below the level of sternomanubrial junction where the UVI is measured, so UVI is considered to be inappropriate for postoperative follow-up.

LVI and CI normally increase in function of age and the rate of increment is greatest between the age of 1 to 10 years, where most corrective operations for funnel chest are performed. So the successive postoperative data can be misinterpreted as worsening or recurrence of depression if normal developmental pattern is not considered. If the correction is complete, the postoperative LVI and CI should be within normal limits of each normogram; which was true for CI but not for LVI. The implication of the deviation of observed LVI from normogram is unclear, but it is reasonable if we consider the fact that correction of the deformity is not getting the normal distance between xyphoid to prevertebral area, and normal LVI, but getting appropriate distance proportional to the distance between retrosternal to prevertebral area, which is usually shorter than normal in funnel chest.

In conclusion, normogram of configuration index can be used as a guideline for satisfactory operative outcome, and other radiologic indices can also be used if normogram is available and correlation to subjective outcome is approved.

## REFERENCES

1. Luc Derveaux, Ignace Clarysse, Ignace Ivanoff : *Preoperative and postoperative abnormalities in chest X-ray indices and in lung function in pectus deformities.* *Chest* 1989 ; 95 : 850-56.
2. Backer OG, Brunner S, Larsen V : *The surgical treatment of funnel chest. Initial and follow-up results.* *Acta Chir Scand* 1961 ; 121 : 253-261.
3. Welch K : *satisfactory correction of pectus excavatum deformity in childhood.* *J Thorac Surg* 1958 ; 36 : 697-713.
4. Humphreys GH, Jaretzki A : *Operative correction of pectus excavatum.* *J Pediatr Surg* 1974 ; 9 : 899-909.
5. Humphreys GH, Jaretzki A. *Pectus excavatum : late results with and without operation.* *J Thorac Cardiovasc surg* 1980 ; 80 : 686-95.
6. Welch, K.J. : *Chest wall deformities.* In *Pediatric Surgery, Edited by T.M.Holder and K.W.Ashcraft.* Philadelphia, W.B.Saunders Co., 1980.
7. Haller JA, Kramer SS, Lietman SA : *Use of CT in selection of patients for Pectus excavatum surgery : a preliminary report.* *J Pediatr Surg* 1987 ; 22 : 904-906.
8. Kazuya Nakahara : *An evaluation of operative outcome in patients with funnel chest diagnosed by means of the computed tomogram.* *J Thorac Cardiovasc Surg* 1987 ; 93 : 577-582.
9. Hummer HP, Willital GH : *Morphologic findings of chest deformities in children corresponding to the Willital-Hummer classification.* *J Pediatr Surg* 1984 ; 19 : 562-67.
10. Shochat SJ : *Moire Phototopography in the evaluation of anterior chest wall deformities.* *J Pediatr Surg* 1981 ; 16 : 353-57.

1. Luc Derveaux, Ignace Clarysse, Ignace Iva-