

## Studies on Intestinal Trematodes in Korea

### XX. Four Cases of Natural Human Infection by *Echinochasmus japonicus*

Byong-Seol Seo, Soon-Hyung Lee, Jong-Yil Chai and Sung-Jong Hong  
*Department of Parasitology and Institute of Endemic Diseases, College of Medicine,  
 Seoul National University, Seoul 110, Korea*

#### INTRODUCTION

The family Echinostomatidae is a group of trematodes infecting the intestine of birds and mammals, and morphologically characterized by the presence of head crown armed with collar spines (Skrjabin, 1956; Yamaguti, 1958). Some members of this family, *i.e.*, 14 species of 5 genera, have drawn medical attentions, because of occasional parasitism in man and causation of intestinal troubles such as abdominal pain and/or diarrhea (Yamashita, 1964; Tani *et al.*, 1974).

*Echinochasmus japonicus*, a species belonging to this family, was first described by Tanabe (1926) from experimental animals such as dogs, cats, rats, mice and birds fed with its metacercariae encysted in the fresh water fishes. Occurrence of its natural human infection has been suspected after the report by Ujiie (1936) who succeeded in human experimental infection to his own body. Thereafter, however, no natural human case has been recorded.

Recently, the authors have found 4 natural human cases of *E. japonicus* infection in Korea, who were concomitantly infected with other intestinal helminths such as *Metagonimus yokogawai* and *Taenia saginata*. In this paper, the cases and morphology of worms were presented, with a brief review of the literature concerning *E. japonicus*.

#### CASES AND WORM COLLECTION

The patients were 3 males aged 33~55 years and 1 female aged 62 years, all residing in a riverside (Tamjin river) village of Kangjin-gun, Jeonranam-do, Korea. This village is a well-known, endemic area of metagonimiasis (Chai *et al.*, 1977), where various kinds of fresh water fishes are abundantly caught and sometimes eaten raw by the people.

Through a field survey in February 1984, the authors tried to enumerate the worm burdens of *M. yokogawai* among the inhabitants and to search for other kinds of intestinal flukes concomitantly infected in them. For recovery of worms from each case, treatment with 10mg/kg single dose of praziquantel and magnesium purgation were performed on some cases revealing high *M. yokogawai* EPG (eggs per gram) in their feces. Immediately after then 4~5 successive diarrheal stools were collected individually and examined under stereomicroscopy. Numerous specimens of *M. yokogawai* were collected, as the results were shown elsewhere (Seo *et al.*, 1985a). But simultaneously, 1~43 specimens of *E. japonicus* were expelled from 4 cases presented above, with/without other kinds of trematodes or cestodes (Table 1).

These *E. japonicus* cases complained some degree of gastrointestinal troubles, especially indigestion and vague abdominal discomfort, however, such symptoms were considered more likely to be due to heavy *M. yokogawai* infection rather than *E. japonicus* alone or due to other

\* This study was supported in part by the Grant from the Green Cross Research Institute (1985).

**Table 1.** Cases of *E. japonicus* and/or other helminth infections

Case No.	Name	Age & Sex	No. of recovered* <i>E. japonicus</i>	Other helminths** recovered (No. worms)
1	CYS	62F	1	<i>M. yokogawai</i> (174)
2	OKS	33M	1	<i>M. yokogawai</i> (63, 587) <i>T. saginata</i> (1)
3	KJH	55M	9	<i>M. yokogawai</i> (52, 030) <i>E. hortense</i> (1) <i>H. h. nocens</i> (2) <i>T. saginata</i> (1)
4	OSI	36M	43	<i>M. yokogawai</i> (25, 858) <i>H. h. nocens</i> (3) <i>P. summa</i> (1) <i>T. saginata</i> (1)

\* Total 54 specimens of *E. japonicus* were obtained.

\*\* *E. hortense*; *Echinostoma hortense*, *H. h. nocens*; *Heterophyes heterophyes nocens*, *P. summa*; *Pygidiopsis summa*.

fluke infections. Their preliminary stool examination revealed numerous eggs of *M. yokogawai* in all of 4 cases, together with *Trichuris trichiura* and/or *Taenia* sp. No echinostomatid eggs were found from them.

Their occupation was all agriculture, but they said that, in high seasons of fishing, they used to go fishing in the river and/or eat the raw flesh of several kinds of fresh water fishes there. But they failed to recall the exact kinds of fish they had eaten recently.

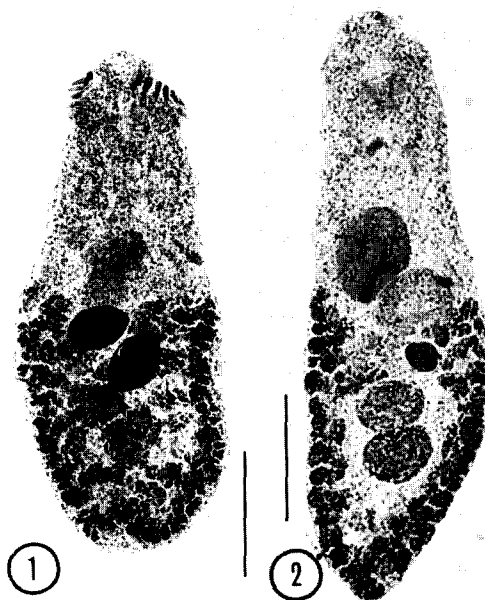
### DESCRIPTION OF WORMS

A total of 54 specimens was collected from 4 patients, but their majority in number revealed more or less destroyed teguments and/or parenchymal organs. Especially some or whole of their collar spines were frequently lost, so that the total number in each specimen was counted with much difficulty except in 2 or 3 intact worms. In general, the shape of worms appeared to have elongated a little than their normal form, to result in a little larger size in length. These morphological alterations were considered due to two or three reasons; the effect of praziquantel used for their treatment, a time gap between worm expulsion and fixation which may lead to deterioration of worms, and/or a possibility of senility in some worms. Relatively intact specimens, 11 in number, were observed in detail,

measured and presented in this paper.

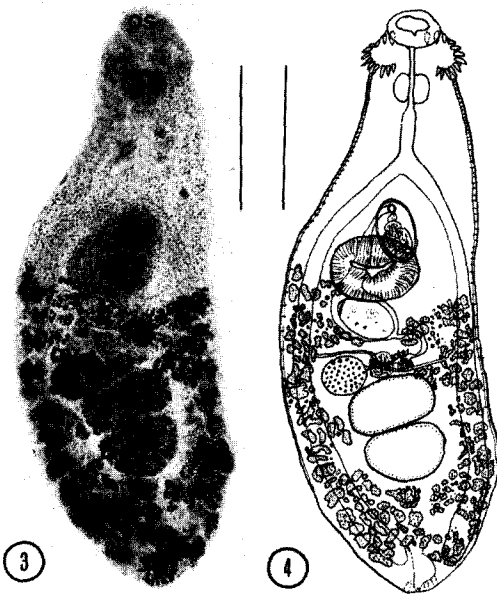
#### *Echinochasmus japonicus* Tanabe, 1926

Body more or less elongated (Fig. 1-4), dor-



**Fig. 1.** A specimen of *E. japonicus* (dorsal view) recovered from a naturally infected man (Case No. 3 in Table 1), showing its prominent head crown with some collar spines, two uterine eggs (black), and several other organs. Acetocarmine stained (Scale: 0.2mm).

**Fig. 2.** Another specimen (ventral view) from Case No. 4, showing ventral sucker, cirrus sac, ovary and two testes. But no egg is seen in this specimen. Acetocarmine stained (Scale: 0.2mm).



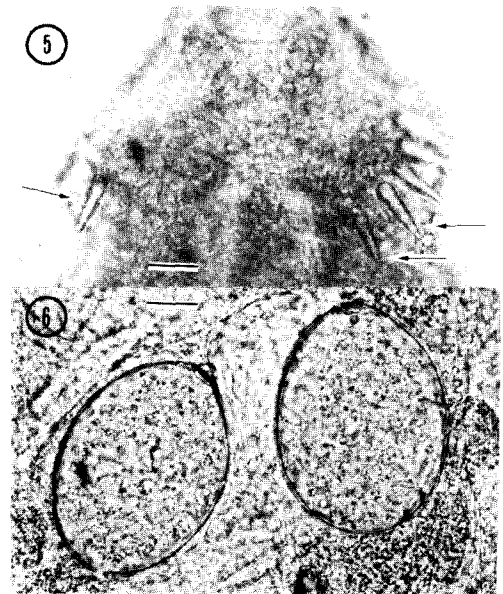
**Fig. 3.** *Ibid*(dorsal view), from Case No. 4, showing oral sucker (os), pharynx (ph), cirrus sac (cs), ventral sucker (vs), one uterine egg (e), ovary (ov), and testes (t). Note the distribution of vitelline glands from the level of ventral sucker to the posterior end of body. Acetocarmine stained (Scale: 0.2mm).

**Fig. 4.** A drawn figure of the worm in Fig. 3 (Scale: 0.2mm).

**Table 2.** Measurements\* of *E. japonicus* recovered from 4 human cases

Item or organ	Measurements (mm)	
	Range	(average)
Body length	0.66 ~0.99	(0.91)
width	0.25 ~0.37	(0.28)
Oral sucker (diam.)	0.055~0.073	(0.065)
Prepharynx (length)	0.024~0.17	(0.041)
Pharynx (diam.)	0.051~0.071	(0.066)
Esophagus (length)	0.079~0.14	(0.11)
Ventral sucker (diam.)	0.095~0.12	(0.11)
Cirrus sac length	0.063~0.12	(0.085)
width	0.032~0.095	(0.050)
Ovary (diam.)	0.044~0.079	(0.060)
Anterior testis length	0.040~0.081	(0.065)
width	0.063~0.15	(0.11)
Posterior testis length	0.055~0.13	(0.096)
width	0.055~0.14	(0.096)
Uterine eggs length	0.076~0.087	(0.083)
width	0.052~0.063	(0.058)

\* Eleven relatively intact worms were measured directly after fixation.



**Fig. 5.** Magnification of the head crown with collar spines (arrows) in a worm from Case No. 4. Note the shape and arrangement of spines (Scale: 0.02mm).

**Fig. 6.** Two uterine eggs of *E. japonicus*, showing their characteristic shape and a small operculum on the upper pole portion (Scale: 0.02mm).

soventrally flat, beset with minute tegumental spines throughout the anterior body but reduced gradually in number toward the posterior body. Head crown distinct, bearing total 24 spines in one row (Fig. 5), 12 on each side, and interrupted at the dorsal side of oral sucker.

Oral sucker subterminal. Pre-pharynx present but variable in length. Pharynx well developed and muscular. Ventral sucker large, well developed, and nearly median and pre-equatorial in position. Esophagus slender and intestine bifurcating at the anterior end portion of cirrus sac. Ceca extending laterally and terminating near the posterior end of body. Excretory bladder Y-form, ending subterminally with a pore. Cirrus sac anterior to ventral sucker, nearly median, globular in shape, and containing a seminal vesicle with ejaculatory duct and female openings. Testes directly tandem near the middle portion of the posterior body and a little transversely

elliptical in shape.

Ovary round, submedian, and connected to seminal receptacle, Mehlis' gland and vitelline ducts. Vitelline glands well developed, variable in size and shape, and extending laterally from the level of ventral sucker down to the posterior end of body. Uterus relatively short and locating between cirrus sac and ovary, with/without one or two eggs. Eggs immature, oval in shape and having a small operculum (Fig. 6).

## DISCUSSION

The echinostomatid flukes infecting man or possibly so have been listed into 14 species in the world, belonging to either of the genera *Echinostoma*, *Echinochasmus*, *Echinoparyphium*, *Euparyphium* or *Himasthla* (Yamashita, 1964; Tani *et al.*, 1974). As for the genus *Echinochasmus*, two species have been included in the list; *E. perfoliatus* since a report was made on a natural human case (Hirasawa, 1928) and *E. japonicus* since an experimental infection of human was reported successful (Ujiié, 1936). In the present study, through the recovery of adult specimens from 4 residents in a riverside village, it was verified for the first time that *E. japonicus* do infect human host in nature. Thus, up to present, total 3 kinds of echinostomes have been recorded from man in Korea; *Echinostoma cinetorchis* (Seo *et al.*, 1980), *E. hortense* (Seo *et al.*, 1983; Ryang *et al.*, 1985) and *E. japonicus* (present study).

There was a little difficulty in the diagnosis of worms obtained from the present human cases, because of their altered and/or deteriorated morphology; slightly elongated body, incompleteness of collar spines, *etc.* In case of collar spines, however, their arrangement and total number were easily figured through a detailed observation and comparison of several partially intact specimens. But their elongated body suggested that they might be smaller-sized worms of *E. perfoliatus*, a morphologically related species to *E. japonicus*. The number and arrangement of collar spines are exactly the same in the two species;

total 24 arranged in a single row.

In general, *E. perfoliatus* reveals more slender and elongated body than *E. japonicus*, and in most cases larger size; from 3~5mm in the former (Tanabe, 1922; Hirasawa, 1928; Skrjabin, 1956) and 0.5~0.9mm in the latter (Skrjabin, 1956; Rim, 1982) to which the present worms were highly compatible. But *E. perfoliatus* could be as small as 0.5~1.0mm (Rim, 1982) and in that case the possibility of the present worms to be *E. perfoliatus* remains. Review of the literature revealed, however, that the number of uterine eggs and size of the eggs have been all the time different between *E. perfoliatus* and *E. japonicus*, and appears to be helpful for their differential diagnosis. It has been a consistent feature that the former contained a considerable number (at least 4, 5 or more) of uterine eggs while the latter had only a few (less than 2 or 3). The egg size of the former was 0.090~0.135mm, while that of the latter 0.077~0.090 mm (Skrjabin, 1956; Rim, 1982).

Slight elongation of the worm body in the present specimens was considered, as mentioned already, due to an effect by the anthelmintic (praziquantel) used for the treatment of these cases. Also the specimens of *M. yokogawai* simultaneously collected from the present cases showed their antero-posteriorly elongated bodies. Other flukes such as *Clonorchis sinensis* (Kim *et al.*, 1980) and *Fibricola seoulensis* (Seo *et al.*, 1985b) were also reported to reveal elongated forms after a contact with praziquantel.

The life cycle of this trematode was successfully studied both in Korea and in Japan. Its snail intermediate host was reported to be *Parafossarulus (Bulimus) striatulus japonicus* in Japan (Yamaguti, 1951), while to be *P. manchouricus* in Korea (Rhee *et al.*, 1983). The second intermediate hosts were at least 24 kinds of fresh and/or brackish water fishes such as *Pseudorasbora parva*, *Plecoglossus altivelis*, *Zacco platypus*, *Carassius carassius* and *Acanthogobius flavimanus* (Tanabe, 1926; Chun, 1964; Komiya, 1965; Lee, 1968; Lee *et al.*, 1979; Joo, 1984), as well as the tadpoles of *Rana rugosa* (experimentally

by Yamaguti, 1951). Animal definitive hosts were various kinds of birds and mammals in nature; *Gallus domesticus* (Kurisu, 1932), *Anas platyrhynchos* var. *domestica* (Eom *et al.*, 1984), *Nycticorax nycticorax* and *Milvus migrans lineatus* (Yamaguti, 1939), and stray dogs (Yoshikawa *et al.*, 1940). Experimentally the worms attained their full growth when infected in the dogs, cats, rats, mice and fowls (Tanabe, 1926; Ujiie, 1936).

As for the fish intermediate hosts in Korea, however, the majority of literature have not clarified the species of *Echinochasmus* metacercariae collected from them (Lee, 1968; Lee *et al.*, 1979; Joo, 1984), even though most of the reports were presumed to have concerned with *E. japonicus*. It was because of a coexistence of *E. perfoliatus* in Korea (Lee, 1979). The size of metacercariae was reported slightly different each other; larger in *E. perfoliatus* (Komiya, 1965), but practically they seemed differed with much difficulty. Therefore, in order to identify the exact species of such metacercariae, their adult worms should be obtained through an experimental infection into final hosts. But it had not been successfully performed in Korea before the present authors (Chai *et al.*, 1985) reported its experimental infection into mice followed by identification of the adult worms to be *E. japonicus*. Moreover, the existence of *E. perfoliatus* should be further verified in Korea.

### SUMMARY

Four cases of human infection by *Echinochasmus japonicus* (Trematoda; Echinostomatidae) were proven by the recovery of adult worms after a treatment with praziquantel (10mg/kg in single dose) and purgation in February 1984 in Korea. The patients were 3 middle-aged men and 1 elderly woman residing in a riverside village of Kangjin-gun (Tamjin river), Jeonranam-do, an ever-known endemic area of metagonimiasis.

The treatment revealed numerous *M. yokogawai* worms together with 1-43 (total 54) specimens of *E. japonicus* and/or a few number of other

kinds of trematodes or cestodes. The patients had gastrointestinal troubles such as indigestion and abdominal discomfort, probably due to these fluke infections. They have been eating some raw flesh of fresh water fishes such as cyprinoid ones or sweetfish caught from the river.

This is the first record of human *E. japonicus* infection in the literature.

### REFERENCES

- Chai, J.Y., Cho, S.Y. and Seo, B.S. (1977) Study on *Metagonimus yokogawai* (Katsurada, 1912) in Korea IV. An epidemiological investigation along Tamjin river basin, South Cholla Do, Korea. *Korean J. Parasit.*, 15(2):115-120.
- Chai, J.Y., Hong, S.J., Son, D.W., Lee, S.H. and Seo, B.S. (1985) Metacercariae of *Echinochasmus japonicus* encysted in a fresh water fish, *Pseudorasbora parva*, and their development in experimental mice. *Korean J. Parasit.*, 23(2):221-229.
- Chun, S.K. (1964) Studies on the experiment of mode of infection of *Clonorchis sinensis* I. Studies on the metacercaria of some trematodes parasitic in fresh water fishes and experimental infection of the cercaria of *C. sinensis* to fresh water fishes. *Bull. Pusan Fish. Coll.*, VI(1):1-14 (in Korean).
- Eom, K.S., Rim, H.J. and Jang, D.H. (1984) A study on the parasitic helminths of domestic duck (*Anas platyrhynchos* var. *domestica* Linnaeus) in Korea. *Korean J. Parasit.*, 22(2):215-221.
- Hirasawa, I. (1928) *Echinochasmus perfoliatus* (Ratz) found in man. *Tokyo Iji Shinshi*, (2577):1328-1334 (in Japanese).
- Joo, C.Y. (1984) Infestation of larval trematodes from fresh-water fish and brackish-water fish in river Hyungsan, Kyungpook Province, Korea. *Korean J. Parasit.*, 22(1):78-84 (in Korean).
- Kim, S.S., Kim, S.J. and Rim, H.J. (1982) Electron-microscopic studies on the effect of praziquantel to *Clonorchis sinensis*. *Korea Univ. Med. J.*, 19(1): 91-105 (in Korean).
- Komiya, Y. (1965) Metacercariae in Japan and adjacent territories. *Progress of Med. Parasitol. in Japan*, 2:1-328.
- Kurisu, Y. (1932) Studies on trematodes which take Japanese house hen as final host. *Kummamoto Igakkai Zasshi*, 8:283-298 (in Japanese).
- Lee, D.M., Ahn, D.H. and Choi, D.W. (1979) Larval

- trematodes from fresh water fish in river Oseap. *Kyungpook Univ. Med. J.*, 20(2):219-233 (in Korean).
- Lee, H.S. (1979) A survey on helminth parasites in Gyeongbug area II. Trematodes. *Korean J. Vet. Res.*, 19:57-61 (in Korean).
- Lee, J.T. (1968) Studies on the metacercariae from fresh water fishes in the Kumho river. *Korean J. Parasit.*, 6(3):77-99 (in Korean).
- Rhee, J.K., Lee, H.I., Baek, B.K. and Kim, P.K. (1983) Survey of encysted cercariae of trematodes from fresh-water fishes in Mangyeong riverside area. *Korean J. Parasit.*, 21(2):187-192 (in Korean).
- Rim, H.J. (1982) Echinostomiasis. CRC Handbook Series in Zoonoses, Vol. III (Trematode Zoonoses). CRC Press Inc., Boca Raton, Florida.
- Ryang, Y.S., Ahn, Y.K., Lee, K.W., Kim, T.S. and Hhan, M.H. (1985) Two cases of natural human infection by *Echinostoma hortense* and its second intermediate host in Wonju area. *Korean J. Parasit.*, 23(1):33-40 (in Korean).
- Seo, B.S., Cha, I.J., Chai, J.Y., Hong, S.J. and Lee, S.H. (1985b) Studies on intestinal trematodes in Korea XIX. Light and scanning electron microscopy of *Fibricola seoulensis* collected from albino rats treated with praziquantel. *Korean J. Parasit.*, 23(1):47-57.
- Seo, B.S., Cho, S.Y. and Chai, J.Y. (1980) Studies on intestinal trematodes in Korea I. A human case of *Echinostoma cinetorchis* infection with an epidemiological investigation. *Seoul J. Med.*, 21(1): 21-29.
- Seo, B.S., Hong, S.T., Chai, J.Y. and Lee, S.H. (1983) Studies on intestinal trematodes in Korea VIII. A human case of *Echinostoma hortense* infection. *Korean J. Parasit.*, 21(2):219-223.
- Seo, B.S., Lee, H.S., Chai, J.Y. and Lee, S.H. (1985a) Intensity of *Metagonimus yokogawai* infection among inhabitants in Tamjin river basin with reference to its egg laying capacity in human host. *Seoul J. Med.*, 26(3):207-212.
- Skrjabin, K.I. (1956) Trematodes of animals and man. Essentials of trematology. Vol. XII. Acad. Sci. USSR, Helm. Lab.
- Tanabe, H. (1922) Studies on trematodes with fresh-water fishes as their intermediate host II. On *Echinochasmus perfoliatus* (Ratz) found in Japan. *Okayama Igakkai Zasshi*, (387):1-20 (in Japanese).
- Tanabe, H. (1926) Studies on trematodes with fresh-water fishes as their intermediate host III. On a new species, *Echinochasmus japonicus* (n.s.). *Nippon Byori Gakkai Kaishi*, 16:295-296 (in Japanese).
- Tani, S., Yoshimura, H., Ohmori, Y., Kamiya, H. and Yamakawa, H. (1974) A case of human echinostomiasis in Akita Prefecture, Japan. *Japanese J. Parasitol.*, 23(6):404-408 (in Japanese).
- Ujii, N. (1936) On the development, the structure of *Echinochasmus japonicus* and its parasitism in man. *Taiwan Igakkai Zasshi*, 35:535-546 (in Japanese).
- Yamaguti, S. (1939) Studies on the helminth fauna of Japan. Part 27. Trematodes of birds, IV. *Japanese J. Zool.*, 8(2):131-210.
- Yamaguti, S. (1951) Zur Entwicklungsgeschichte von *Echinochasmus japonicus* Tanabe, 1926 mit besonderer Berücksichtigung der Struktur der Cercariae. *Okayama Arch. Med. Fak.*, 7:338-342.
- Yamaguti, S. (1958) Systema helminthum. Vol. I (Part I & II) The digenetic trematodes of vertebrates. Interscience Publishers Inc., New York and London.
- Yamashita, J. (1964) Echinostome. *Progress of Med. Parasitol. in Japan*, Vol. 1:289-313.
- Yoshikawa, M., Miyata, I. and Uesugi, S. (1940) Additional findings on the trematode parasites in stray dogs in Kobe city. *Nippon Juigaku Zasshi*, 2:450-464 (in Japanese).

## 한국의 장흡충에 관한 연구

### XX. *Echinochasmus japonicus*의 人體感染 4例

서울대학교 의과대학 기생충학교실 및 풍토병연구소

徐丙高 · 李純炯 · 蔡鍾一 · 洪性琮

극구흡충류(echinostomes)의 하나인 *Echinochasmus japonicus* 成蟲이 1984년 4월 인체로부터 회수되어 이 흡충에 의한 자연 인체감염이 처음으로 증명되었다. 환자는 요꼬가와흡충 유행지로 알려진 전남 탐진강 유역 강진군에 거주하는 33~55세 남자 3명과 62세 여자 1명, 도합 4명으로 이들을 10 mg/kg praziquantel로 치료하고 下劑를 사용한 후 설사변에 배출된 모든 吸蟲 및 條蟲을 수집하였다.

蟲體 수집결과 많은 수의 요꼬가와흡충이 배출된 것이 확인되었으나 이들과 함께 1~4 종류의 다른 吸蟲 또는 條蟲이 발견되었고 특히 *E. japonicus* 1~43마리(총 54마리)가 검출되었다. 환자들은 이들 장내 윤충류의 복합감염으로 소화불량, 복부불쾌감 등 위장관 증상을 호소하였고 강 유역에서 각종 잉어科 어류나 은어를 잡아 生食해 온 경력이 있었다.

이들 극구흡충은 길이 0.66~0.99mm이었고, 頭冠 주위의 頭棘이 총 24개로 口吸盤 背側에서 연결이 끊어져 있었고, 子宮內 蟲卵數가 2개 이내인 점, 蟲卵의 크기가 76~87 $\mu$ m(길이)인 점 등으로 *Echinochasmus japonicus* Tanabe, 1926으로 同定되었다.