

Surgery for Severe Mitral Valve Disease with Giant Left Atrium, the Effect of Plication Procedure on Left Atrium

Tsuyoshi Fujita, M.D.*

1. Preface

The effectiveness of surgical treatment for the valvular heart diseases has been generally accepted due to the stabilization of its operative outcome, those patients who have left untreated or refused to receive surgical treatment come to the subject of surgical intervention now a day. These patients are obviously very ill, characteristically represent 100% of its cardio-thoracic ratio that is accompanied with extremely dilated left atrium. The enlargement of left atrium usually comes with mitral valvular lesion but extremely dilated left atrium is considered as the final clinical manifestation of mitral valvular disease. In this report, we are dealing with the pathophysiology of this particular condition as well as our surgical treatment of plication procedure toward this extremely dilated left atrium.

2. Definition of giant left atrium and pathophysiological classifications

It is well known that the markedly increased cardio-thoracic ratio is resulted from the enlargement of left atrium as well as right atrium. However, the major problem caused by this extremely dilated or giant left atrium is produced by the

compression to the surrounding structure such as to the left ventricle and bronchopulmonary complex. We defined the giant left atrium as those findings which has these ill effect of compression by extremely dilated left atrium. According to the study of these patients with giant left atrium, we classified them into three types by their characteristic pathophysiological manifestation.

1) Abnormal configuration and contraction of left ventricle (type I)

The compression of postero-basal wall of the left ventricle produced by the downward expan-

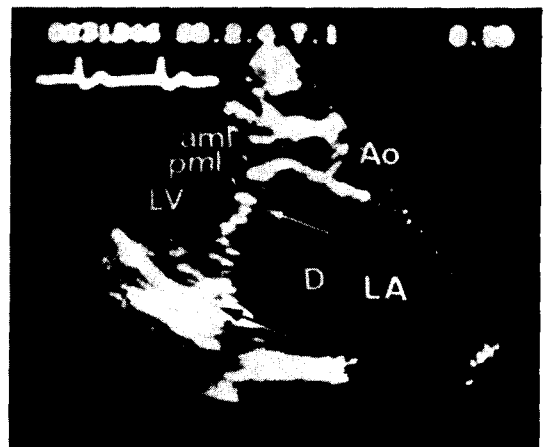


Fig. 1. Real-time two-dimensional echocardiogram in the long-axis view showing extremely dilated left atrium (LA) and the inward bending position of the posterobasal wall of the left ventricle (LV) in diastole. Ao, Aorta. aml, Anterior mitral leaflet. pml, Posterior mitral leaflet. D, The length of the bending segment.

* Department of Cardiovascular Surgery, National Cardiovascular Center, 5-125, Fujishirodai, Suita, Osaka, 565, JAPAN.

sion of dilated left atrium is visualized by real-time, two-dimensional echocardiogram (Fig. 1).⁵⁾ We defined as giant left atrium if this length of compression of postero-basal segment of left ventricular wall is exceeded over 30 mm by echocardiographic examination and those patients

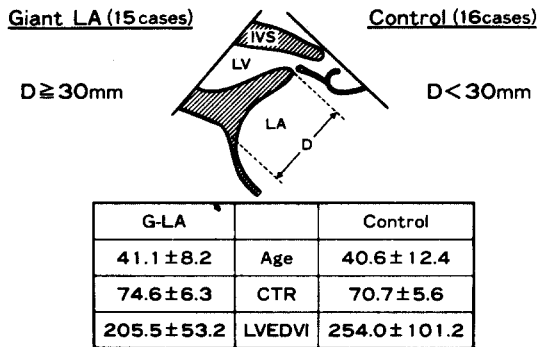
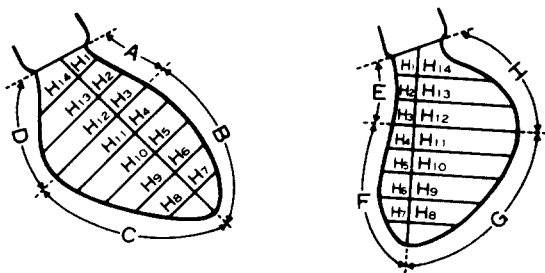


Fig. 2.



● Shortening rate of Hemi-axes(%)

$$S = \frac{H_{\text{end-diast.}} - H_{\text{end-syst.}}}{H_{\text{end-diast.}}} \times 100$$

● Mean shortening rate of each segment (%)

- RAO Projection
- Anterobasal S₁₋₃ (A)
 - Anteroapical S₄₋₇ (B)
 - Posteroapical S₈₋₁₁ (C)
 - Posterobasal S₁₂₋₁₄ (D)
- LAO Projection
- Septal S₁₋₃ (E)
 - S₄₋₇ (F)
 - Posterolateral S₈₋₁₁ (G)
 - S₁₂₋₁₄ (H)

Fig. 3. Formula for the calculation of a shortening rate of each segment of the left ventricle by hemi-axis method.

with less than 30 mm were considered as control group (Fig. 2, D). The mode of contraction of individual segment of left ventricle in giant left atrium of 15 patients and control group of 16 patients was observed using hemi-axis method from the left ventriculogram taken at the left (LAO) and right oblique (RAO) positions (Fig. 3). Age distribution, cardio-thoracic ratio and left ventricle end diastolic volume index (LVEDVI) were equivalent in both groups (Fig. 2). In giant left atrium group, the posterobasal segment of left ventricle (D&H) showed completely different contraction mode comparing to the same portion of control group which demonstrated minus contraction ratio. This means that the paradoxical movement was induced by compression of left atrium and we classified this as type I (Fig. 4).

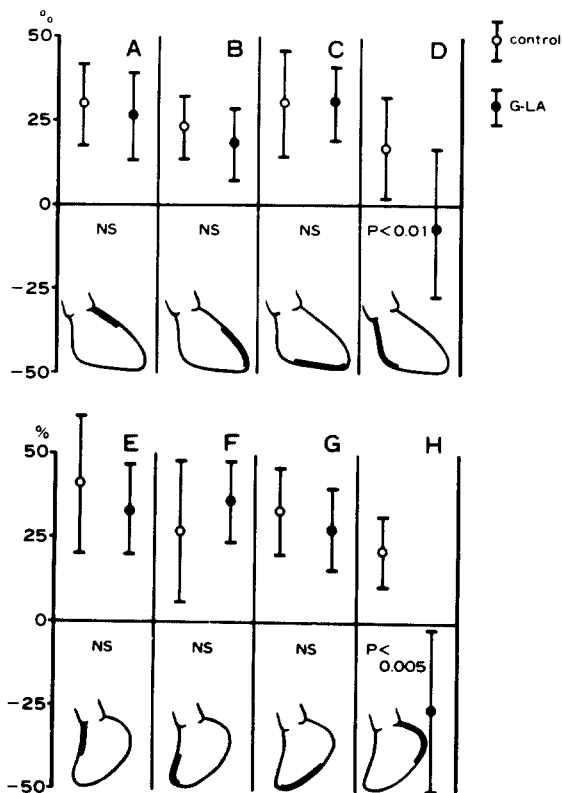


Fig. 4. Shortening are of each segment of the left ventricle in the giant left atrium and control group.

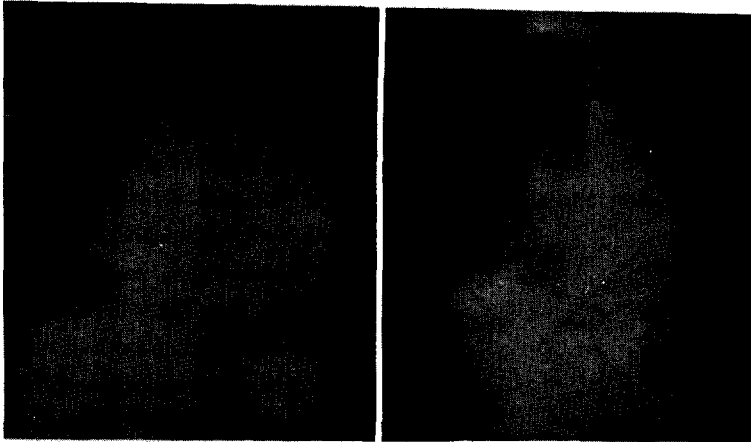


Fig. 5. Elevation and narrowing of left main bronchus in type II of giant left atrium

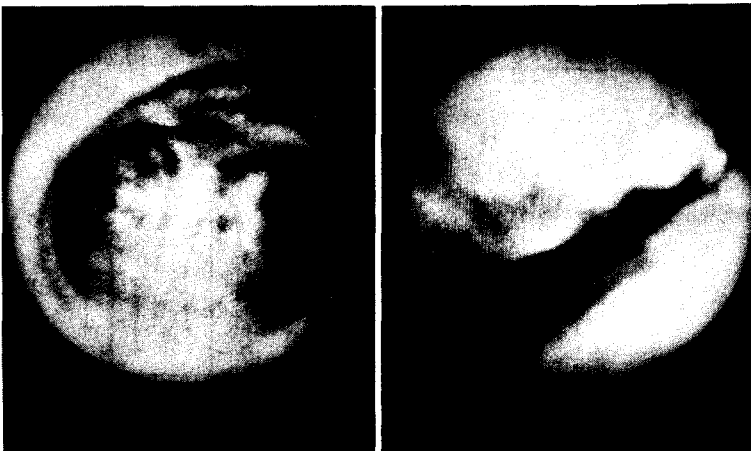

Fig. 6. Bronchoscopic findings in type of giant left atrium

Type I+III

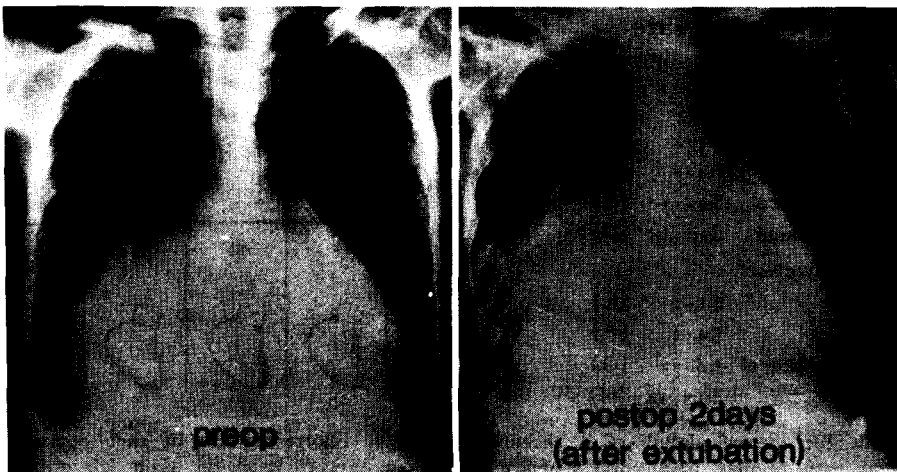

Fig. 7. Chest x-ray film of type III

2) Broncho-pulmonary compression (Type II & III)

Left-upward extension of left atrium is resulted as the elevation of left main bronchus as well as compression to bronchial tree. Fig. 5 and 6 is illustrating widening of carinal angle and the elevation of left main bronchus demonstrating by plain chest rentogenogram and broncho-scopic examination. We classified this as type II. We also experienced that rightward expansion of left atrium resulted right lung atelectasis (Fig. 7). Fig. 8 is illustrating bronchoscopic finding of middle and lower lobe bronchus in right lung which showed dominant narrowing of lumen. We classified this pathology as type III.

3. Materials

Total number of giant left atrial patients according to our criteria were 81, their age and sex distributions are shown in Fig. 9. Pathology of mitral valvular lesion were, 19 of stenotic lesion, 29 of stenosis and regurgitation and 33 patients of regurgitation group. The combined valve lesions were, 45 with tricuspid lesion and 15 patients with aortic valve pathology. Our surgical procedures applied were illustrating at Fig. 10, only seven patients were operated by mitral valve plasty and mitral valve replacement was undertaken rest of all the patients.

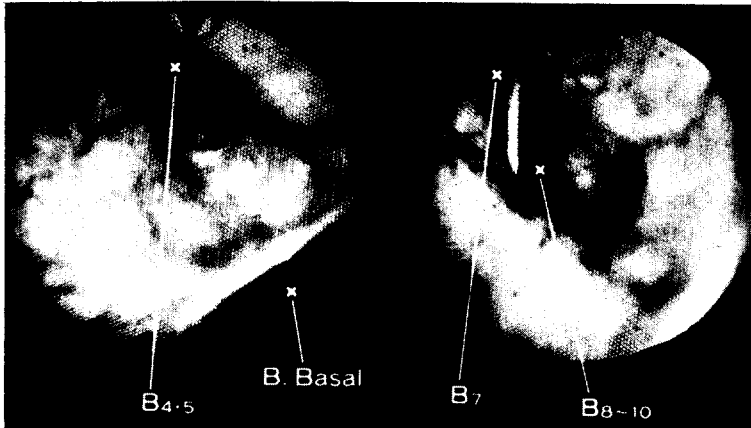


Fig. 8. Bronchoscopic findings in type III

Fig. 9. Valve lesions in patients with giant left atrium

Classification of giant left atrium	Type I	Type I+II	Type I+III	Type I+II+III	Type II+III
No. Patient	36	16	11	14	4
Age(average)	47.4	47.9	47.4	49.0	47.8
Male/Female	6/29	3/13	6/5	0/14	2/2
MS (r)	8	4	3	3	1
MSR	12	6	4	5	2
MR (s)	16	6	4	6	1
Associated TR	17	13	7	8	4
Associated aortic valve lesion	8	0	2	3	2

Fig. 10. Surgical procedures in patients with giant left atrium

Classification of giant left atrium	Type I	Type I+II	Type I+III	Type I+II+III	Type II+III
No. Patient	36	16	14	44	4
MVP	3	0	1	0	0
MVP+TAP	1	0	0	1	0
MVP+AVP+TAP	0	0	0	1	0
MVR	12	3	2	4	0
MVR+TAP	12	13	6	6	2
MVR+AVP	4	0	0	0	0
MVR+AVP+TAP	2	0	0	0	1
MVR+AVR	1	0	1	0	0
MVR+AVR+TAP	1	0	1	2	1

Legend : MVP, mitral valvuloplasty. TAP, tricuspid annuloplasty. AVP, aortic valvuloplasty. MVR, mitral valve replacement. AVR, aortic valve replacement.

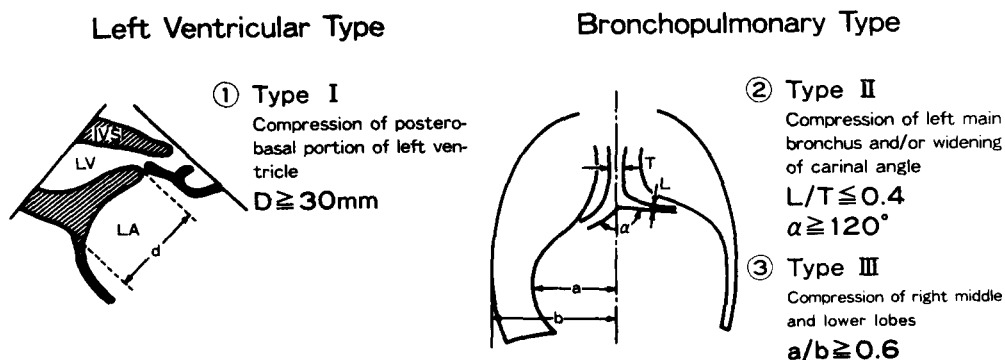


Fig. 11. Patho-morphological classification and criteria for plication of giant left atrium

4. Surgical Indications and Operative Techniques for Giant Left Atrium

Our surgical indications to individual type are demonstrating in Fig. 11. These criterias were, length of D demonstrated by echocardiography was over 30 mm in type 1, widening of carinal angle over 120 degree and/or the degree of stenosis of left main bronchus by representing to the ratio of diameter of left main bronchus to trachea (L/T) was below 0.4 in type II and right cardiothoracic ratio was over 0.6 in type III. The plication procedures for each type of pathology were explaining as follows. For type I, left atrial wall between posterior leaflet of mitral

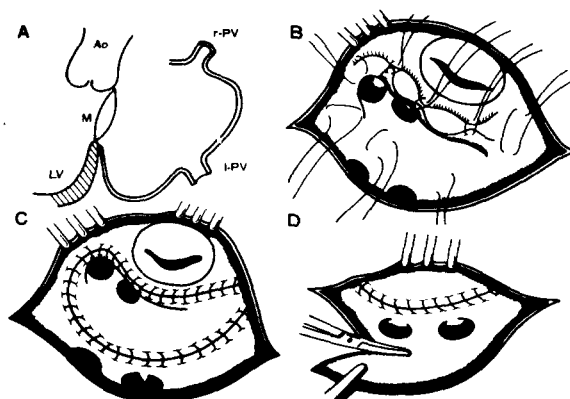


Fig. 12. Plication procedure for giant left atrium

ring and ostium of left pulmonary vein was semi-lunarily plicated including ostium of left appendage

down to the level of diaphragma (para-annular plication). For type II, plication was attempted at cranial site of left atrium including ostium of left appendage along to the ostium of left superior pulmonary vein towards bilateral ostium of pulmonary vein (superior or cranial plication). The resection of right side of left atrium was also added between inter-atrial sulcus and right side ostium of pulmonary vein. These plication procedures were done in continuity at majority of cases (Fig. 12).

5. Operative Results

The operative results for giant left atrium is illustrating in Fig. 13. Patients were classified into two groups according to the procedure whether plication was employed or not. In the group of patients who did not received plication procedure or were incompletely done, for instance such as plication was applied only toward one type of lesion and left untreated for associated type of pathology. The hospital deaths were recorded as 10 among 20 patients (50%) of high mortality, comparing to 4 death among 61 patients (6.6%) in group of patients where all the necessary procedure were employed. The incidence of serious postoperative complications such as low output syndrome and respiratory failure were also recorded as high as 61.1% and 66.6% in non or incomplete plication group respectively. This incidences were low of 6.7% and 5.0% in complete plication group respectively and their post-operative managements were much smoother in this group

The changes in cardiac index in the post-

Fig. 13. Effects of plication procedure for giant left atrium

plication procedure	non and incomplete	complete
No. Patient	20	61
LOS	11/18 (61.1%)	4/60 (6.7%)
Resp. failure	12/18 (66.6%)	3/60 (5.0%)
Hospital death	10 (50.0%)	4 (6.6%)

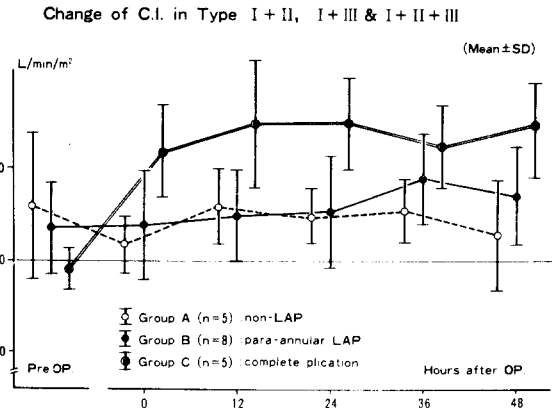
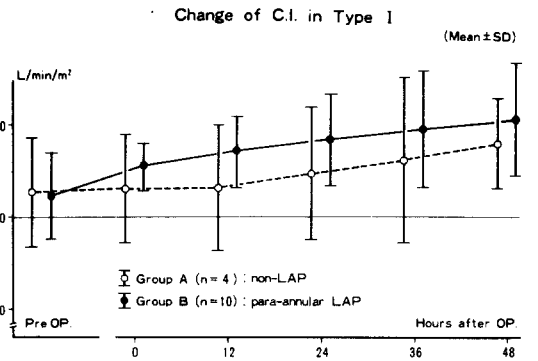


Fig. 14. Changes of cardiac index in postoperative period

operative period is demonstrating in Fig. 14. The cardiac output in a patient who received para-annular plication for this type I lesion was fairly high in comparison to non-plicated patient. In combined type lesions, postoperative changes in cardiac procedure were all attempted comparing to the group of patient where plications were incompletely done. Same improved results were also seen in postoperative respiratory condition where high respiratory rate and elevated PCO₂ were observed in incompletely plicated group (Fig. 15).

In postoperative follow up study, marked improvement of cardiothoracic ratio, reduction of narrowing at left main bronchus and carinal angle as well as right side cardio-thoracic ratio were also obtained (Fig. 16). In type I lesion where para-annular plication was applied, the compression configuration (D value) was markedly

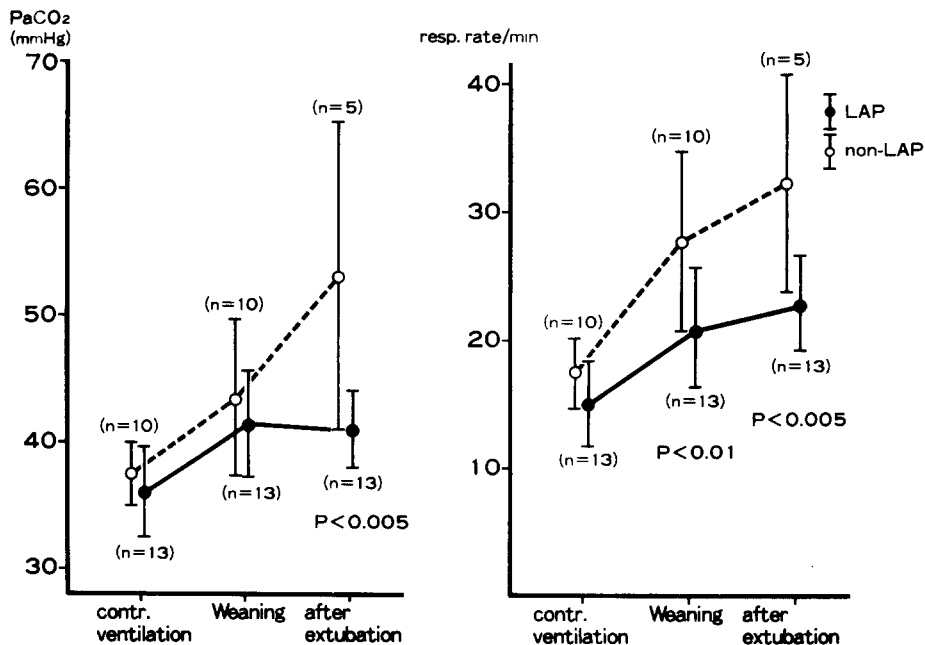


Fig. 15. Effects of plication for giant left atrium on respiration

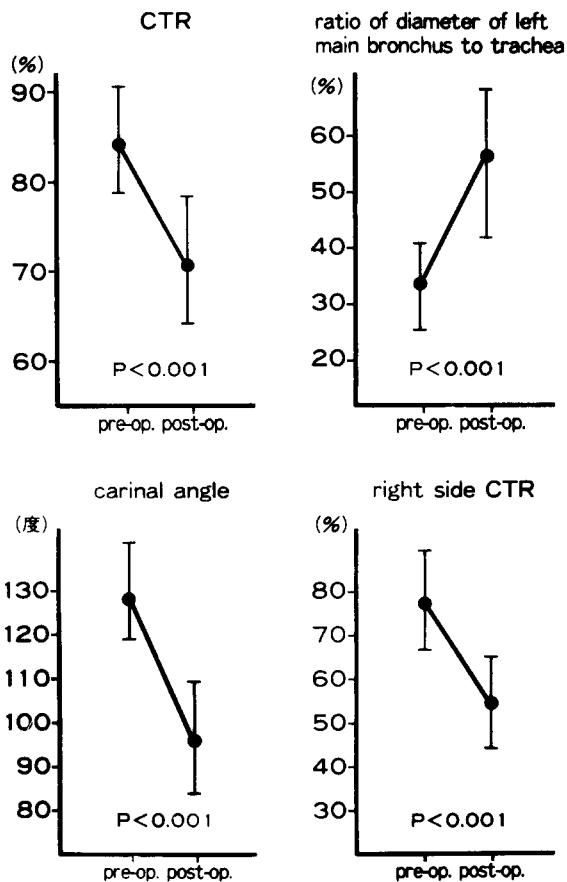


Fig. 16. Effects of plication for giant left atrium

reduced postoperatively and angle of θ which was made between the plane of aortic valve annulus and mitral valve annulus showed widening, returning to the normal configuration. (Fig. 17).

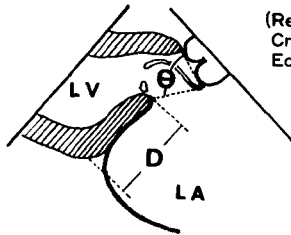
6. Discussion

The report on giant left atrium was already seen at 1901 in the literature, death due to the compression of vertebral column by enlarged left atrium was accounted and explained as a terminal clinical manifestation of mitral valve disease.¹⁾ In our own experience with this advanced situation, a patient died of esophageal obstruction before any surgical intervention was attempted. Several surgical treatments have been proposed by reducing left atrium by plicating redundant atrial wall, however, their operative outcome were so far not effective.²⁾³⁾⁴⁾ We have been studying the patho-morphological conditions which were produced by this disorder, established our own method of plication and have established our own method of plication and have been obtaining improved operative results.⁵⁾⁶⁾⁷⁾⁸⁾⁹⁾¹⁰⁾¹¹⁾

MATERIALS

Plication Group			non-Plication Group
External	Internal (I)	Internal (II)	10 cases
3 cases	6 cases	7 cases	

METHOD



(Real-time
Cross-sectional
Echo cardiography)

D: The length of the postero-basal part of LV compressed by large LA
 θ: The angle between aortic valve annulus and mitral valve annulus

Results

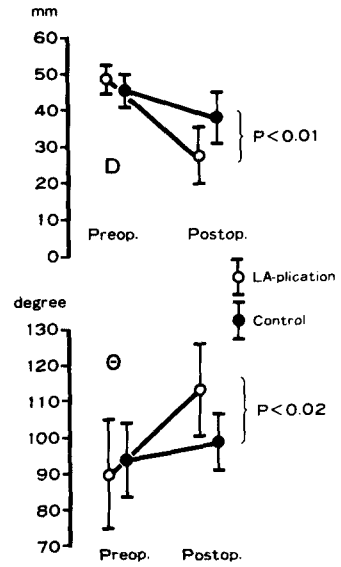
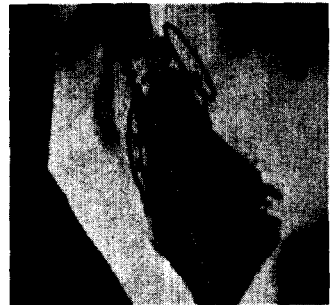
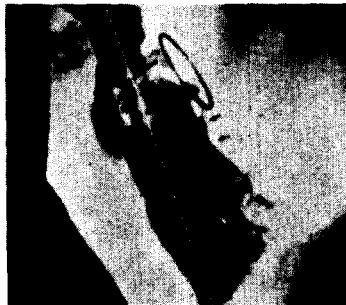
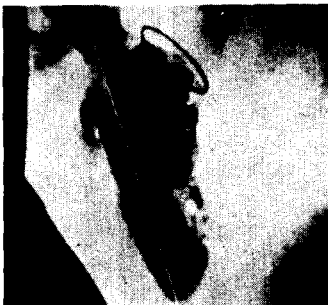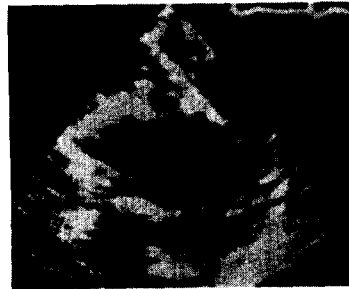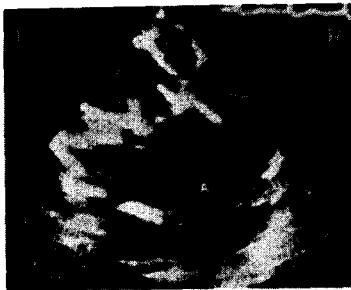Fig. 17.

(End-Systole)

(Mid-Diastole)



(End-Systole)

(Early-Diastole)

(End-Diastole)

Fig. 18. Echocardiographic (upper panel) and angiographic findings (low panel) of mitral valve replacement with Hancock-Xenograft in type I of giant left atrium

Fig. 18 is an echocardiographic and left ventriculographic finding in a patient who was treated with mitral valve replacement by Hancock xenograft. The stent of Hancock valve came to attach to ventricular septum at diastole. The posterior wall of left ventricle was compressed by left atrium and this segment was shifted anteriorly in diastole by paradoxical movement and came too close to ventricular septum. In left ventriculography, plane of valvular ring of Hancock xenograft was found to become parallel with ventricular septum in diastolic phase, therefore, inflow pattern of blood showed directing toward the ventricular septum with the angle of 90 degree, then shifted toward ventricular apex. Contrarily in systolic phase, postero-basal segment of left ventricle also showed paradoxical motion of backward movement comparing to forward movement of rest of ventricular wall. We were quite aware of this ill effect of paradoxical movement, we also found damage on the muscle of ventricular septum produced by the compression of stent at autopsy finding, we have invented our para-annular plication procedure try to minimize this abnormal movement.⁶⁾

Since we have employed our procedure in 1979, we did not see the attachment of artificial valve to ventricular septum, plane of inserted artificial valve ring was faced toward ventricular apex, resulted in marked improvement of inflow pattern to the left ventricle.⁶⁾¹⁰⁾ For type II and III lesion, we have encountered serious difficulty in ICU much easier and smoother.⁸⁾⁹⁾ As a result, mortality was markedly improved, Fig. 19 is pre-and postoperative chest rentogen film of a patient who had combined type I, II and III lesions. Clear improvement is demonstrating even in immediate postoperative period after complete plication procedures which were employed toward each type of lesion. We have also found marked reduction of left atrial volume after plication procedure by CT study, volume became as small as equivalent to that of mild degree of valvular disorder.

7. Conclusion

Operative results of 81 patients of severe mitral valvular disease with giant left atrium was presented. Following extensive study on the pathomorphology, we have clearly established definition

Type I + II + III

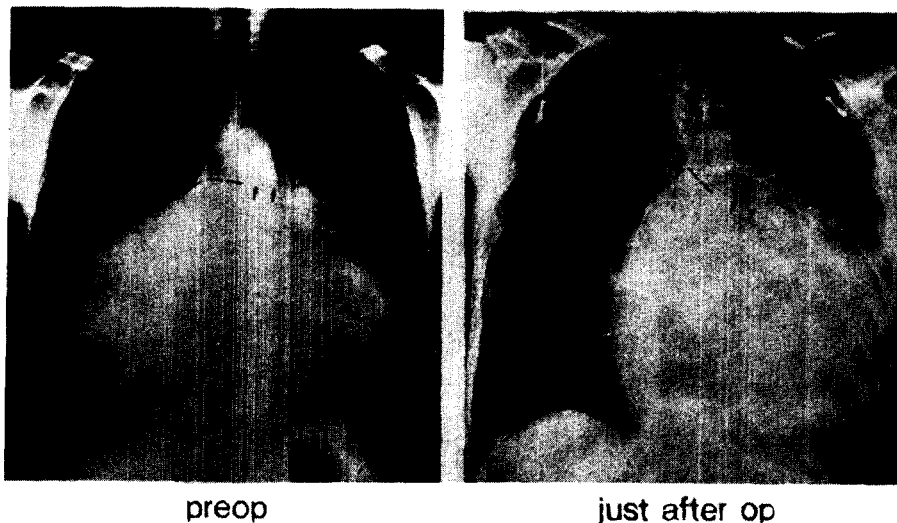

Fig. 19. Effects of plication procedure for giant left atrium

of giant left atrium as well as indication of plication procedures and techniques. As the result, we have achieved marked improvement on operative outcome for the patients with severe mitral valve disease.

REFERENCES

1. Owen, I., & Fenton, W.V. : *A case of extreme dilatation of the left auricle of the heart*, *clin. Soc. Trans.* 34:183, 1901
2. Johnson, J., Danielson, G.K., MacVangh, H. & Joyner, C.R. : *Plication of the giant left atrium at operation for severe mitral regurgitation*, *Surg.* 61:118, 1967
3. Knudsen, D.F., Daily, P.O., Stinson, E.B., & Shumway, N.E. : *Surgical treatment the giant left atrium*, *S.G.O.*, 128:565, 1969
4. LeRoux, B.T., Gotsman, M.S. : *Giant left atrium*, *Thorax* 25:190, 1970
5. Beppu, S., Kawazoe, K., Nimura, Y., Nagata, S., Park, Y., Sakakibara, H., & Fujita, T. : *Echocardiographic study of abnormal position and motion of the postero-basal wall of the left ventricle in cases of giant left atrium*, *Am. J. Cardiol.* 49:467, 1982
6. Fujita, T., Kawazoe, K., Beppu, S., & Manabe, H. : *Surgical treatment on mitral valvular disease with giant left atrium, the effect of paraannular plication on left atrium*, *Japn. Circulation J.*, 46:420, 1982.
7. Kawazoe, K., Takahara, Z., Tanaka, K., Ego, Y., Hayashi, K., Fujii, N., Kosakai, Y., Ohara, K., Kito, Y., Fujita, T., Manabe, H., & Beppu, S. : *Giant left atrium in mitral valve disease : A new plication procedure to releave the compressions of left ventricular wall, left bronchus and right lung*, *J. Japn. Assoc. Thoracic Surg.* 84:31, 1983 (in Japanese)
8. Takahara, Y., Kawazoe, K., Tanaka, T., Hayashi, K., Kosakai, Y., OHara, K., Kito, Y., Fujita, T., & Manabe, H. : *Giant left atrium in mitral valvular disease, the effect of left atrium plication for the compression to the lung bronchus*, *J. Japn. Assoc. Thoracic Surg.* 31:191, 1983 (in Japanese)
9. Takahara, Y., Kawazoe, K., Tanaka, K., Fujita, T., Kozuka, T., & Manabe, H. : *Giant left atrium in mitral valvular disease, postoperative respiratory distress by the compression to the lung and bronchus.*, *J. Japn. Assoc. Thoracic Surg.*, 31:225, 1983 (in Japanese)
10. Fujita, T., Kawazoe, K., & Beppu, S., : *Giant left atrium, its definition and pathophysiology*, *Recent advances in Cardiovasc. Dis.*, 4:52, 1983 (in Japanese)
11. Kawazoe, K., Beppu, S., Takahara, Y., Nakajima, N., Tanaka, K., Ichihashi, K., Fujita, T., & Manabe, H.: *Surgical treatment of giant left atrium combined with mitral valvular disease*, *J. Thorac & Cardiovasc. Surg.*, 85:885, 1983