

\*, \*\*, \*\*, \*\*\*  
\*  
\*\*  
\*\*\* ( )  
e-mail : hjkim@handong.edu

## Focal Liver Mass Detection and Analysis in Ultrasound Images

Seung-Kang Lee\*, Eun-Bi Park\*\*, Ho-Joon Kim\*\*, Byung-Gap Hwang\*\*\*  
\*Dept. of Information and Communication, Handong University  
\*\*Dept. of Computer Science and Electrical Engineering, Handong University  
\*\*\*MediSensor, Inc.

(microbubble)  
(Hough transform)  
TIC(time intensity curve)  
가 MRF(Markov random field)  
(transit time)  
field)  
가

1.  
CT(computer tomography)  
MRI(magnetic resonance imaging)  
가 가  
TIC(time intensity curve) ROI  
4  
(parametric imaging) MRF  
(Markov random field)  
가  
가

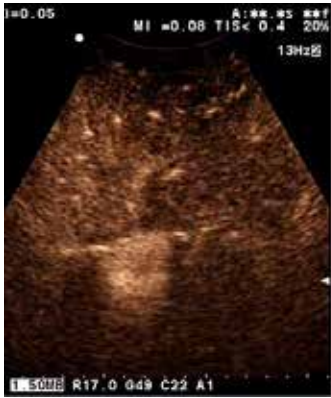2.  
[2]. 가  
TIC  
(edge)  
(Hough transform) 가

가

( 1)

[3]

ROI



( 1)

$$(x, y) \quad a \quad y \quad b^2$$

$$(1) \quad y = ax + b \quad (1)$$

$$(x, y) \quad r \quad x \quad q \quad (r, q) \quad (2)$$

가

(voting)

$$r = x \cos q + y \sin q \quad (2)$$

(circular Hough transform)

$$(a, b) \quad , \quad r \quad (3)$$

ROI

(voting)

$$r^2 = (x - a)^2 + (y - b)^2 \quad (3)$$

(4)

( 2)

ROI

$a, b, r$  가

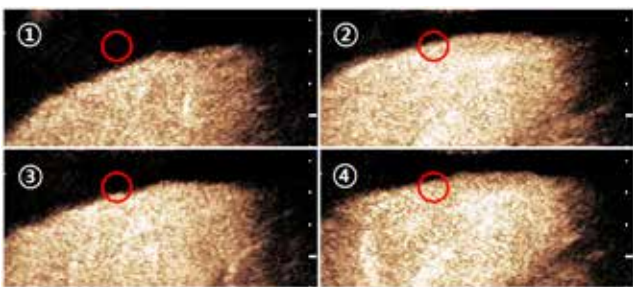
ROI 가  
TIC

가 가

$$x = a + r \cos q$$

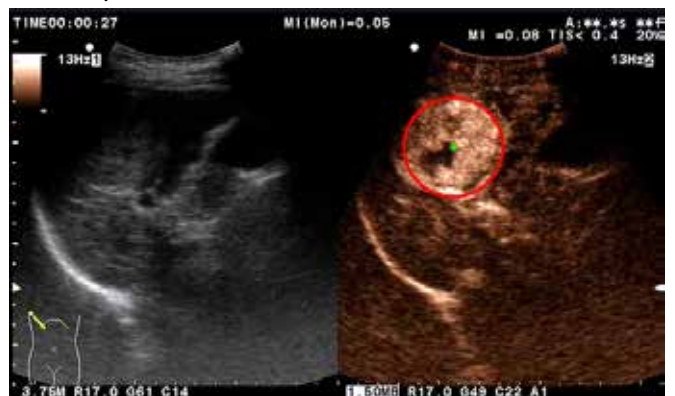$$y = b + r \sin q \quad (4)$$

( 3)



( 2)

ROI




( 3)

( )

(circular mask)

3.



< 1 >

Unipolar +		Hyper-enhanced	
Unipolar -		Hypo-enhanced	
Bipolar +/-		Hyper-enhancement / hypo-enhancement	
Bipolar -/+		Hypo-enhancement / hyper-enhancement	

MRF

(5)  $h_s$  MRF  $s$  (neighborhood)

$X_s$  가 가

가

$$P(X_s = x_s | X_r = x_r, r^1 s) = P(X_s = x_s | X_r = x_r, r^1 h_s) \quad (5)$$

$\{s, h_s\}$  Gibbs  $c$  (clique)

(6)

$$p(w) = \frac{1}{Z} \exp \left( - \frac{1}{T} \sum_c V_c(w) \right) \quad (6)$$

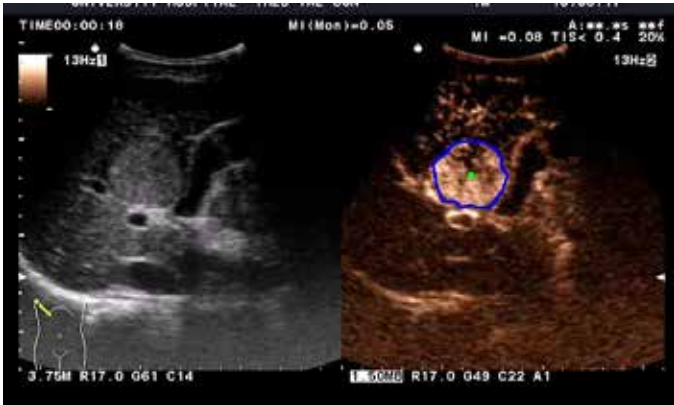$V_c$

4. ROI

가 ROI

[4.]

5. ( 5)



(No. 2012H1B8A2025800).

( 5)

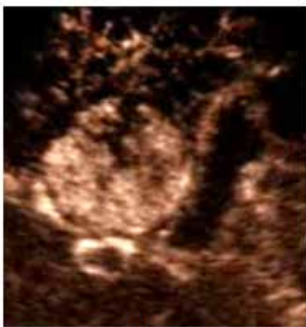( 6)

(b)

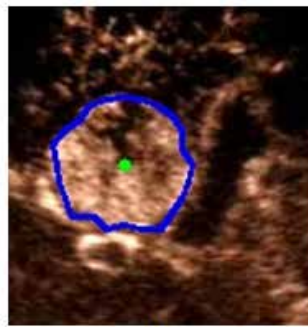
, (c)

(d)

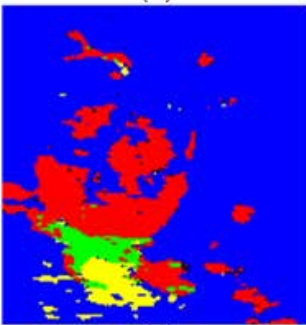
MRF



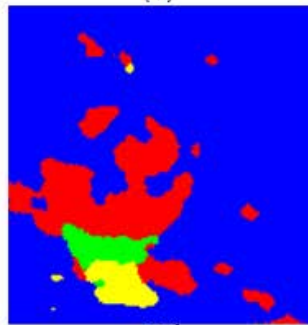
(a)



(b)



(c)



(d)

( 6)

: (a)

(b)

(c)

(d) MRF

[1] A K P Lim, S D Taylor-Robinson, N Patel, R J Eckersley, R D Goldin, G Hamilton, G R Foster, H C Thomas, D O Cosgrove, M J K Blomley "Hepatic Vein Transit Time using a Microbubble Agent Can Predict Disease Severity Non-invasively in Patients with Hepatitis C," *Liver*, Vol.54, pp.128-133, 2005.

[2] J. Hohmann, T. Albrecht, C.W. Hoffmann, K.-J. Wolf, "Ultrasonographic Detection of Focal Liver Lesions: Increased Sensitivity and Specificity with Microbubble Contrast Agents" *European Journal of Radiology*, Vol.46, pp.147-159, 2003.

[3] Wei Lu, Jingu Tan, "Detection of Incomplete Ellipse in Images with Strong Noise by Iterative Randomized Hough Transform," *Pattern Recognition*, Vol.41, pp.1268-1279, 2008.

[4] Nicolas G. Rognin, Marcel Arditi, Laurent Mercier, Peter J. A. Frinking, Michel Schneider, Genevieve Perrenoud, Anass Anaye, Jean-Yves Meuwly, and Francois Tranquart, "Parametric Imaging for Charactering Focal Liver Leisions in Contrast-Enhanced Ultrasound," *IEEE Transaction on Ultrasonics, Ferroelectrics, and Frequency Control*, Vol.57, No.11, pp.2503-2511, 2010.

6.

가

MRF