

Application of artificial neural network to differential diagnosis of lung lesion: Preliminary results

Haejun Lee*, Yukyung Lee*, Kyung-Hoon Hwang*
 *Dept. of Nuclear Medicine, Gil Hospital
 e-mail : forrest88@hanmail.net

Summary

It is difficult to differentially diagnose between lung cancer and benign inflammatory lung lesion due to high false positive rate on F-18 FDG-PET. We investigated whether application of artificial neural network to this diagnosis may be helpful.

We reviewed the medical records and F-18 FDG PET images of 12 patients, selecting clinical and PET variables such as SUV. For selected variables and confirm, multilayer neural perceptron was applied in cross-validation method and compared to visual interpretation.

Neural network correctly classified the lung lesions in 83%, and reduced greatly the false positive rate. However, false negative rate was not influenced.

Application of neural network to the differential diagnosis between lung cancer and benign inflammatory lesion may be helpful. Further studies with more patients are warranted.

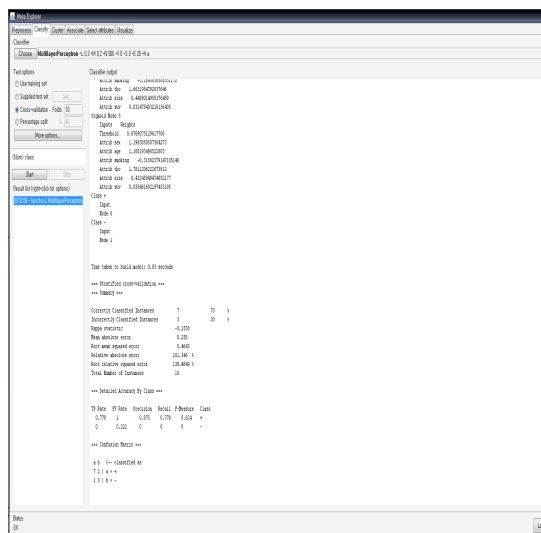
1. Introduction

The lung cancer is one of the most common malignant tumors, in the developed countries. However, it is difficult to differentially diagnose between lung cancer and benign inflammatory lung lesion in a tuberculous-endemic countries because CT and PET shows a high false positive rate.

Artificial neural network have been applied to many fields of medical decision procedure [1-3]. Recently, Vesselle et al demonstrated the potential of artificial neural network to differential diagnosis of lung lesion on F-18 F-18 FDG-PET. Therefore, we investigated whether application of artificial neural network to this diagnostic procedures may be helpful.

2. Methods

It is very difficult to directly assess the lesion seen on CT or F-18 FDG-PET. Thus, we reviewed the medical records and F-18 FDG PET images of 12 patients, selecting clinical and PET variables such as SUV. For selected variables and confirm, we applied multilayer neural perceptron in cross-validation method, using WEKA tool(version 3.4) and compared to visual interpretation by experienced interpreters.



(Fig. 2) Application of WEKA Tool: Result report

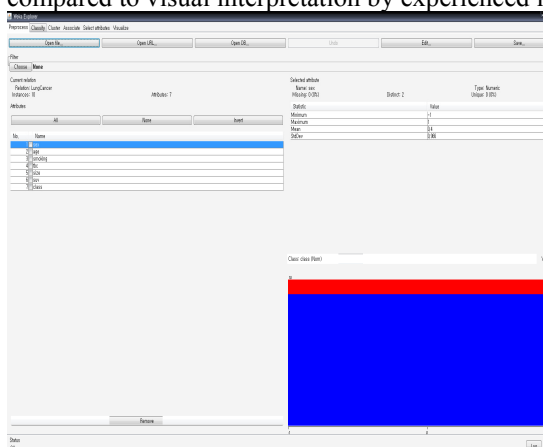
3. Results

Results showed correct classified instance of 70%, incorrect classified instance of 30%, TP(true positive) rate of 0.778, precision of 0.875, recall of 0.778 and F-Measure of 0.824.

Application of neural network yielded correct classification of the lung lesions in 83%, and reduced greatly the false positive rate compared to the visual interpretation. However, false negative rate was not influenced.

4. Conclusion and future work

Our preliminary results show that application of neural network to the differential diagnosis between lung cancer and benign inflammatory lesion may be helpful. However, there is more work that needs to be done to validate this method completely and further studies with more patients are warranted.



(Fig. 1) Application of WEKA Tool

References

- [1] Ravdin PM, Clark GM. A practical application of neural network analysis for predicting outcome of individual breast cancer patients. *Breast Cancer Research and Treatment* 1992;22:285-293.
- [2] Burke HB, Goodman PH, Rosen DB, Henson DE, Weinstein JN, Harrell FE, et al. Artificial neural networks improve the accuracy of cancer survival prediction. *Cancer* 1997;79:857-82.
- [3] Djavan B, Remzi M, Zlotta A, Seitz C, Snow P, Marberger M. Novel artificial neural network for early detection of prostate cancer. *2002;20:921-29.*
- [4] Vesselle H, Turcotte E, Wiens L, Haynor D. Application of a neural network to improve nodal staging accuracy with F18-F-18 FDG PET in non-small cell lung cancer. *J Nucl Med.* 2003;44:1918-26.