

Associated lesions of Biceps tendon in shoulder pathology

성균관대의대 삼성서울병원 정형외과교실

유재철 · Mukesh Laddha, M.D.

INTRODUCTION

The long head of biceps tendon (LHBT) is the proverbial stepchild of the shoulder. The history of our understanding of the LHBT is long and full of controversies. First reported case of LHBT dislocation was in 1694 by William Cowper(1). MRI and Arthroscopy had provided valuable information about LHBT. In 1985 Andrews (2) described Superior Labrum lesions and in 1990 Snyder(3) coined the term SLAP lesion. Walch(4) in 1990 described Biceps Pulley and its Lesion. Though described 300 years ago still role of LHBT and its lesions remains controversial.

ANATOMY

It arises most commonly from superior glenoid labrum (45%), supraglenoid tubercle (30%) and from both (25%). Approximately 9cm long and 5~6 mm in diameter. It is an intraarticular but extrasynovial structure. Superficial surface is vascular and deep sliding surface is avascular. It is innervated by network of sensory sympathetic fibres which may play a role in pathogenesis of shoulder pain(5). Various anatomical variations like congenital absence, synovial mesentery, fusion with rotator cuff, bifid tendon, etc exists.

FUNCTION

It is still a matter of debate. It has no primary function in shoulder but multiple secondary roles like, humeral head depressor, secondary stabilizer of glenohumeral joint, participation in abduction with arm in external rotation, checkrein ligament at extreme range of motion, etc.

CLASSIFICATION

1. Slatkin and Aalto Classification:

- Type A: Impingement tendinitis
- Type B: Subluxation of the biceps
- Type C: Attrition is primary

2. Habermeyer and Walch Classification:

I: Origin

II: Interval Lesions

- A: Biceps tendinitis
- B: Isolated ruptures
- C: Subluxation:

- Type I: Superior

- Type II: At the groove

- Type III: Mal or Non union of lesser tuberosity

III: Associated with RCT

- A: Tendinitis

- B: Dislocation

Type IA: Extra-articular with partial subscapularis tear

Type IB: Extra-articular with intact subscapularis

Type II: Intra-articular

- C: Subluxation with RCT

- D: LHB rupture with RCT

3. TLC Classification:

Tendon: Stable, Unstable, Tendinitis, Rupture

Location: Origin, Interval, Groove, Musculotendinous junction

Cuff: Intact, Partial tear, Complete tear, Tendinosis

4 New Classification system of LHB Instability taking into account Direction and Extent of Instability, Macroscopic Lesion of LHB and concomitant Cuff tear—Laurent Lafosse (6):

LHB—Direction: Anterior, Posterior, or both

Extent: None, Subluxation or Dislocation

DIFFERENTIAL DIAGNOSIS

Typically tendinitis of LHB is seen in association with other lesions. Primary, isolated biceps tendinitis is a diagnosis of exclusion. Generally seen with RCT, Impingement Syndrome, Shoulder Instability, and Glenoid Labral Tears without Instability, Adhesive Capsulitis, Arthritis, and Coracoid Impingement Syndrome.

TREATMENT

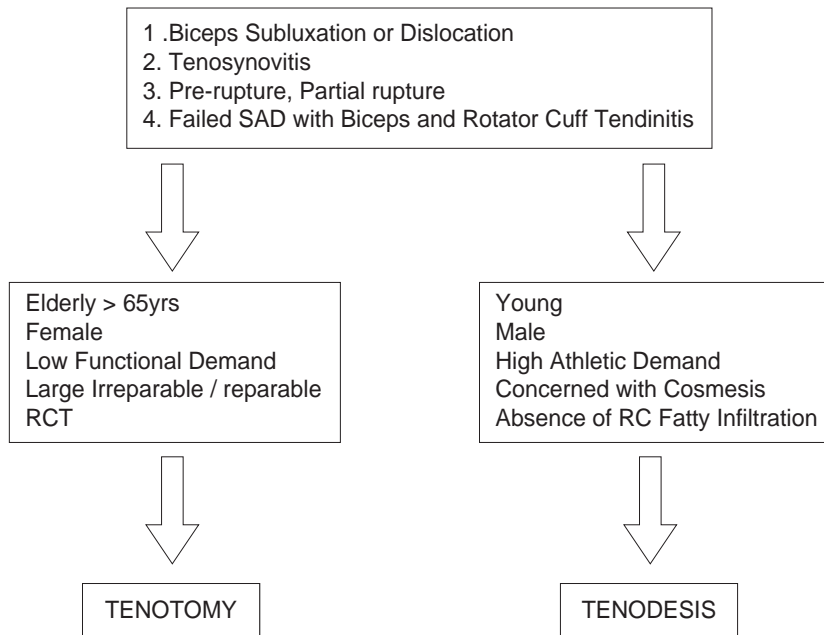
1. Conservative

Rest, Physiotherapy, Analgesia, Local Steroid or Anaesthetic injection—results guarded as most of the lesions of LHB are mechanical which requires surgery.

2. Surgical

Acromioplasty, Coracoplasty, Isolated Synovectomy, Biceps Relocation and Reconstruction of pulley, Proximal Reinsertion—Not useful for Isolated LHB lesion.

MAIN SURGICAL TREATMENT IS TENODESIS OR TENOTOMY



Lesion Grade: Normal (0), Minor (I) or Major (II)

Cuff Lesion: Intact (A), Partial Tear (B), Complete Tear (C)

5. Mechanical lesions

Instability (medial or lateral)

Entrapment (hourglass or rupture)

Traumatic lesions or Sports related injuries

CLINICAL FEATURES

Rarely an isolated lesion it is usually associated with other pathologies of shoulder, especially rotator cuff tear and instability. Chronic and rarely acute anterior shoulder pain, radiating down the arm, rest pain, aggravates on overhead activities, mainly atraumatic & rarely traumatic.

O/E: Tenderness in groove. Various tests Yergasons, Speed, Instability test, O'Brien's, etc but none of this is confirmative. Loss of terminal active and passive ER & FE.

RARELY A CLINICAL DIAGNOSIS

INVESTIGATIONS

1. Plain radiography: limited benefit—calcification, bony deformity, osteophytes, cystic changes in LT. Useful views are AP in external rotation, axillary, Fisk view—for groove
2. Arthrography: first imaging techniques to identify pathology reliably. Now used in conjunction with MRI or CT.
3. Ultrasonography: Non invasive but highly operator dependent. It has 49% sensitivity and 97% specificity(7). It also had positive predictive value of 100% and negative predictive value of 71%. So a normal sonography does not preclude an anatomic biceps tendon lesion.
4. Magnetic resonance imaging: Widely used for RCT but less reliable in diagnosis of biceps tendon pathology, 37% concordance between MRI and Arthroscopy (8).
5. Arthroscopy: best method for definitive diagnosis of intra-articular biceps tendon. Both static and dynamic examination is possible; other causes of anterior shoulder pain can be identified. Disadvantage—invasive procedure under general anaesthesia.

1. Types of Tenodesis

Arthroscopic and Arthroscopic Assisted Mini Open

1. Open Subpectoral Bone Tunnel Biceps Tenodesis
2. Arthroscopic Suture Anchor Biceps Tenodesis
3. Open Subpectoral Intereference Screw Technique
4. Arthroscopic Intereference Screw Technique
5. Arthroscopic Percutaneous Intra-articular Transtendon Technique

2. Advantages of Tenodesis

1. Re-establish the resting muscle length
2. Prevent muscle atrophy
3. Avoid cramping pain
4. Maintain elbow flexion and supination strength
5. Avoid cosmetic deformity (Popeye)

3. Advantages of Tenotomy

1. Technically Simple and easy
2. No Hardware or Neurology Problems
3. Less post operative rehabilitation

REFERENCES

1. Cowper W : Myotomia Refomata.London: Printed from Sam Smith and Ben Walford,1694,p75
2. Andrews J, Carson W, Mcleod W: Glenoid Labrum Tears related to Long Head of Biceps.Am J Sports Med 13:337-341,1985.
3. Snyder SJ, Karzel RP, Del Pizzo W.et al: SLAP Lesions of the Shoulder.Arthroscopy 6:274-279,1990.
4. Walch G: La Pathologie de La Longue portion du biceps.Presented at conference d' enseignement de La SOFCOT,Paries,December 1993.
5. Alpantaki K, McLaughlin D, Karogogeos D, Hadji pavlou A, Kontakis G. Symathetis and sensory neural elements in the tendon of the long head of the biceps.J Bone Joint Surg(Am)2005;87-A:1580-3.
6. Laurent Lafosse, M.D.,Youri Reiland, M.D., Gloria P.Baier, M.D., Bruno Toussaint, M.D., and Bernhard Jost, M.D: Anterior and posterior Instability of the Long Head of the Biceps Tendon in Rotator Cuff Tears: A New Classification Based on Arthroscopic Observations. Arthroscopy 2007;23:73-80.
7. Armstrong A,Teefey SA,Wu T,et al. The efficacy of Ultrasound in the diagnosis of Long Head of Biceps Tendon pathology. J Shoulder Elbow Surg 2006;15:7-11.