

:

가

가

( )

(synovial

chondromatosis),

(osteochondritis dissecans)

:

(osteophyte)

(coronoid process)

(olecranon)

가

(coronoid fossa)

(olecranon fossa)

(fossa)

가

가

(loose body)

(locking),

(creiptus),

(Fig. 1).

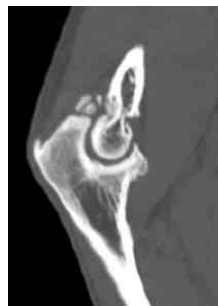
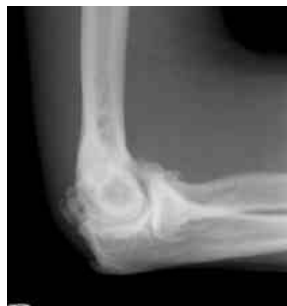
Fig. 1.

CT

(coronoid process)

(olecranon)

(coronoid fossa)

(olecranon fossa)

body)

(locking),

(creiptus)

(loose

:

( ; debridement),

(fenestration),

Outerbridge-Kashiwagi procedure(O-K procedure)  
 - (ulnohumeral arthroplasty)

Morrey

10)

2,12,13,15,17,18)

: 가

(Fig. 2-1).

(osteotome) burr  
 (postero-central portal)  
 3~4 mm drill bit  
 , burr

(olecranon fossa)  
 (coronoid fossa)  
 (Fig. 2-2 & 2-3).

(radiocapitellar)

(posterior interosseous nerve)  
 (radial notch)

(radial neck)

:

18)

가  
 ( O-K

procedure)

2)

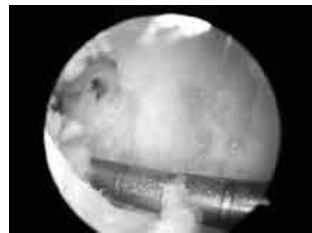
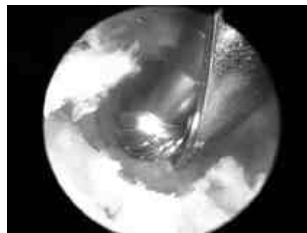
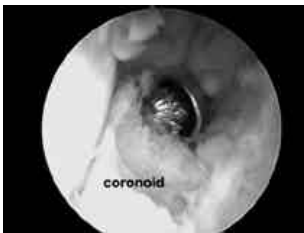
Fig. 2.

(olecranon fossa)

burr

가 (B)

burr

(A),

(C).

가

가

(intrinsic)

(extrinsic)

(interposition arthroplasty),

(distraction arthroplasty),

(total elbow replacement)

(arthroplasty)

1

가  
가 2 mm

3

ossification)

(ectopic

가

(anterior capsule)

가

가

가

가

가

(medial collateral ligament)

(posterior band)

3,9,20)

(isometricity) 가

(Fig. 1-1).

가

가

(posteromedial capsule)

(Fig. 1-2).

:

가

가

가

(ulnar neuropathy):

가

(entrapment syndrome)

(cubital

tunne)

가

가

가

가

,  
,  
,  
,

가

가

가  
(retractor)

gutter

basket punch

5).

가

가

shaver

brachial<sub>관</sub>

probe

shaver

brachial<sub>관</sub>

shaver

reverse basket resector

(Fig. 3-1).

(Fig. 3-2).

portal

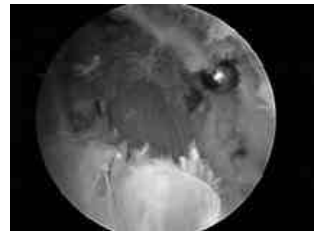
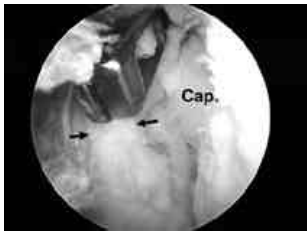

Fig. 3.

resector

(3-1).

reverse basket  
(3-2). cap; capitellum.

Morrey

column procedure<sup>8)</sup>

column procedure

column procedure

가

1,4,6,7,11,14,16,19)

가

## REFERENCES

- 1) Ball, C. M.; Meunier, M.; Galatz, L. M.; Calfee, R.; and Yamaguchi, K.: Arthroscopic treatment of post-traumatic elbow contracture. *J Shoulder Elbow Surg*, 11(6): 624-9, 2002.
- 2) Cohen, A. P.; Redden, J. F.; and Stanley, D.: Treatment of osteoarthritis of the elbow: a comparison of open and arthroscopic debridement. *Arthroscopy*, 16(7): 701-6, 2000.
- 3) Itoh, Y.; Saegusa, K.; Ishiguro, T.; Horiuchi, Y.; Sasaki, T.; and Uchinishi, K.: Operation for the stiff elbow. *Int Orthop*, 13(4): 263-8, 1989.
- 4) Jones, G. S., and Savoie, F. H., 3rd: Arthroscopic capsular release of flexion contractures (arthrofibrosis) of the elbow. *Arthroscopy*, 9(3): 277-83, 1993.
- 5) Kelly, E. W.; Morrey, B. F.; and O'Driscoll, S. W.: Complications of elbow arthroscopy. *J Bone Joint Surg Am*, 83-A(1): 25-34, 2001.
- 6) Kim, S. J.; Kim, H. K.; and Lee, J. W.: Arthroscopy for limitation of motion of the elbow. *Arthroscopy*, 11(6): 680-3, 1995.
- 7) Kim, S. J., and Shin, S. J.: Arthroscopic treatment for limitation of motion of the elbow. *Clin Orthop Relat Res*, (375): 140-8, 2000.
- 8) Mansat, P., and Morrey, B. F.: The column procedure: a limited lateral approach for extrinsic contracture of the elbow. *J Bone Joint Surg Am*, 80(11): 1603-15, 1998.
- 9) Moritomo, H.; Tada, K.; and Yoshida, T.: Early, wide excision of heterotopic ossification in the medial elbow. *J Shoulder Elbow Surg*, 10(2): 164-8, 2001.
- 10) Morrey, B. F.: Primary degenerative arthritis of the elbow. Treatment by ulnohumeral arthroplasty. *J Bone Joint Surg Br*, 74(3): 409-13, 1992.
- 11) Nowicki, K. D., and Shall, L. M.: Arthroscopic release of a posttraumatic flexion contracture in the elbow: a case report and review of the literature. *Arthroscopy*, 8(4): 544-7, 1992.
- 12) O'Driscoll, S. W.: Arthroscopic treatment for osteoarthritis of the elbow. *Orthop Clin North Am*, 26(4): 691-706, 1995.
- 13) Ogilvie-Harris, D. J.; Gordon, R.; and MacKay, M.: Arthroscopic treatment for posterior impingement in degenerative arthritis of the elbow. *Arthroscopy*, 11(4): 437-43, 1995.
- 14) Phillips, B. B., and Strasburger, S.: Arthroscopic treatment of arthrofibrosis of the elbow joint. *Arthroscopy*, 14(1): 38-44, 1998.
- 15) Redden, J. F., and Stanley, D.: Arthroscopic fenestration of the olecranon fossa in the treatment of osteoarthritis of the elbow. *Arthroscopy*, 9(1): 14-6, 1993.
- 16) Savoie, F. H., 3rd, and Field, L. D.: Arthrofibrosis and complications in arthroscopy of the elbow. *Clin Sports Med*, 20(1): 123-9, ix, 2001.
- 17) Savoie, F. H., 3rd; Nunley, P. D.; and Field, L. D.: Arthroscopic management of the arthritic elbow: indications,

- technique, and results. *J Shoulder Elbow Surg*, 8(3): 214-9, 1999.
- 18) Steinmann, S. P.; King, G. J.; and Savoie, F. H., 3rd: Arthroscopic treatment of the arthritic elbow. *J Bone Joint Surg Am*, 87(9): 2114-21, 2005.
  - 19) Timmerman, L. A., and Andrews, J. R.: Arthroscopic treatment of posttraumatic elbow pain and stiffness. *Am J Sports Med*, 22(2): 230-5, 1994.
  - 20) Wada, T.; Ishii, S.; Usui, M.; and Miyano, S.: The medial approach for operative release of post-traumatic contracture of the elbow. *J Bone Joint Surg Br*, 82(1): 68-73, 2000.