

SECOND TIME DISLOCATION : HOW TO MANAGE

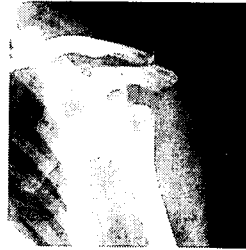Yong Girl Rhee, MD
Jeong Han Ha, MD

*Shoulder & Elbow Clinic
Kyung Hee University Hospital
Seoul, Korea*

KMC shoulder & elbow

FIRST TIME VS SECOND TIME IS THERE ANY DIFFERENCE?

DISLOCATION VS INSTABILITY



KMC shoulder & elbow

Younger patients with primary anterior dislocations have a higher rate of recurrence

Rowe (1956) 324 dislocation

*94% younger than 20 years old
14% older than 40 years old*

KMC shoulder & elbow

Simonet and Cofield (1983) 116 dislocation

*66% in younger than 20, 17% in 20 to 40, 0% in older than 40
younger than 20 80% in athletes, 30% in non-athletes*

KMC shoulder & elbow

The majority of all recurrences occur within the first two years after the first traumatic dislocation

Rowe (1956)

Patients with 2 or more dislocations during the
first 2 to 5 years had a 78% chance of having
another episode of instability

Hovelius (1996)

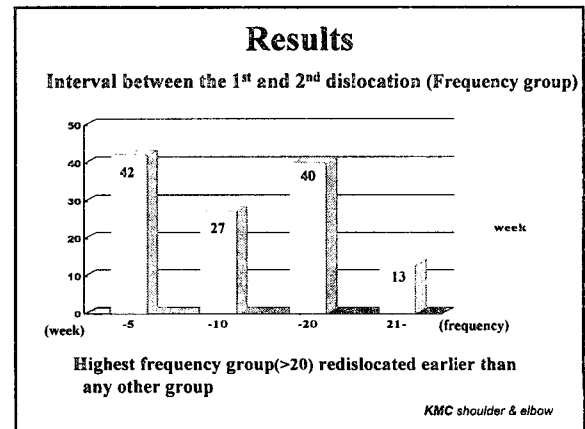
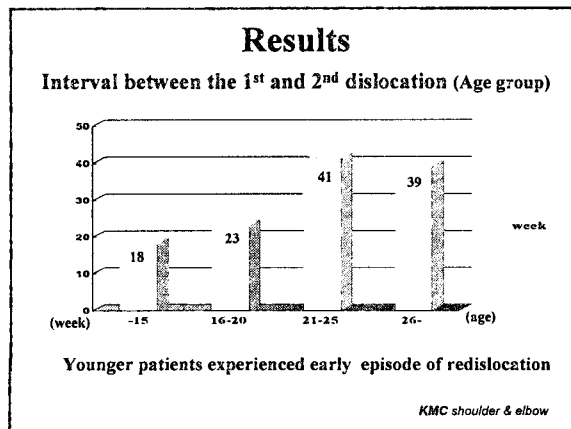
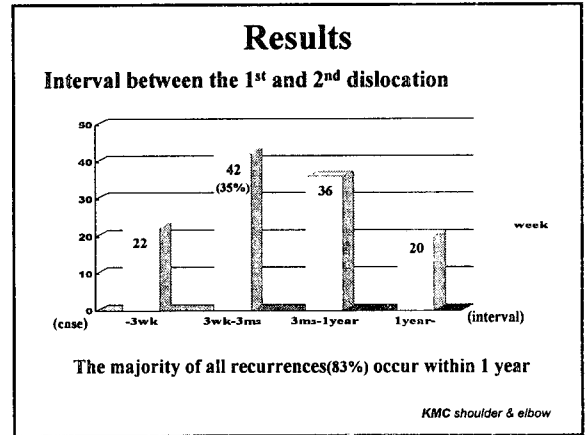
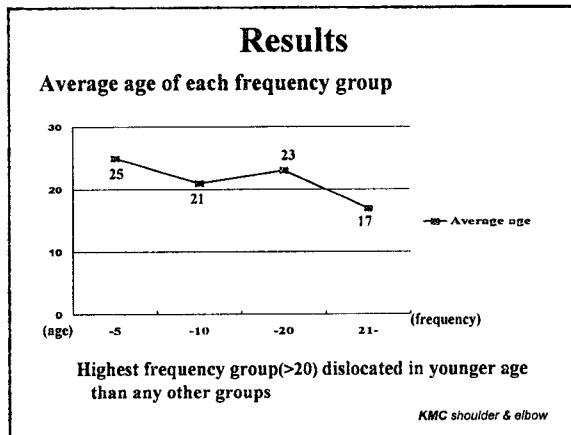

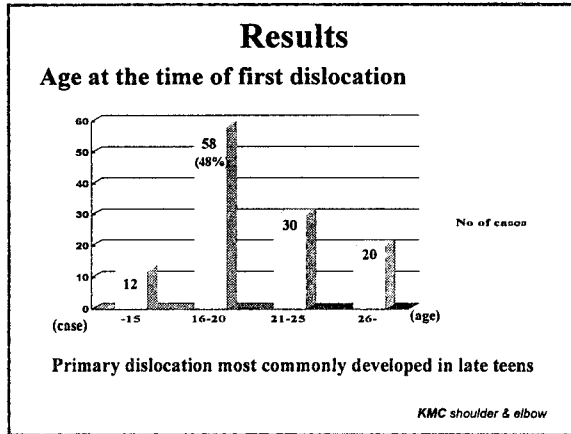
KMC shoulder & elbow

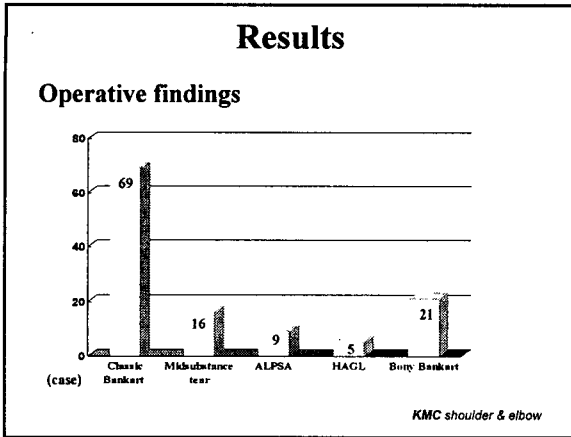
From Jan. 2002 to Dec. 2002 Total 125 Anterior Shoulder Instability

Statistical analysis of 120 cases

Age at the time of first dislocation : av. 21 yrs
Number of total dislocation : av. 25
Interval between 1st and 2nd dislocation : av. 30wks

KMC shoulder & elbow





Results

Operative findings (Age group)

	-15yrs	-20	-25	26 -
Classic Bankart	8	38	10	13
Midsubstance tear		7	8	1
ALPSA		3	5	1
HAGL		1	2	2
Bony Bankart	4	9	5	3

KMC shoulder & elbow

Results

Operative findings (Frequency group)

	-5	-10	-20	21-
Classic Bankart	16	20	16	17
Midsubstance tear	5	4	3	4
ALPSA	2	3	2	2
HAGL	2	2	1	
Bony Bankart	1	3	6	11

Bony Bankart lesion was most common finding in highest frequency group

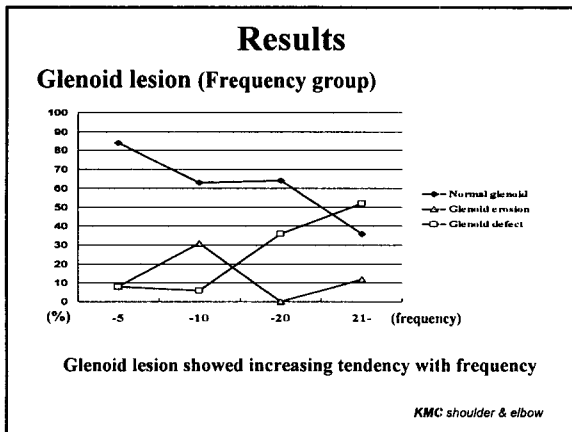
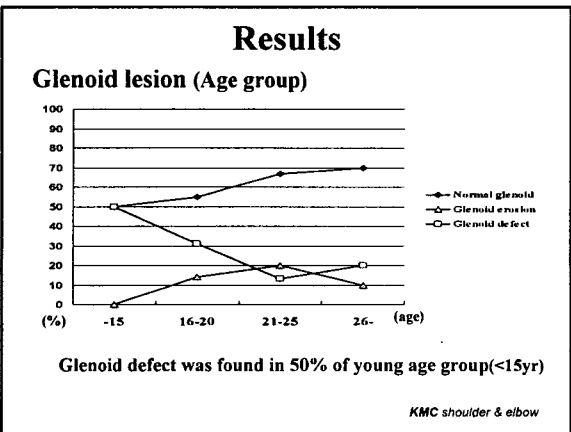
KMC shoulder & elbow

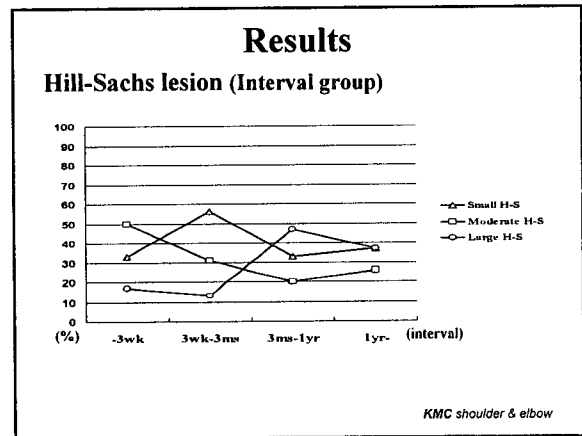
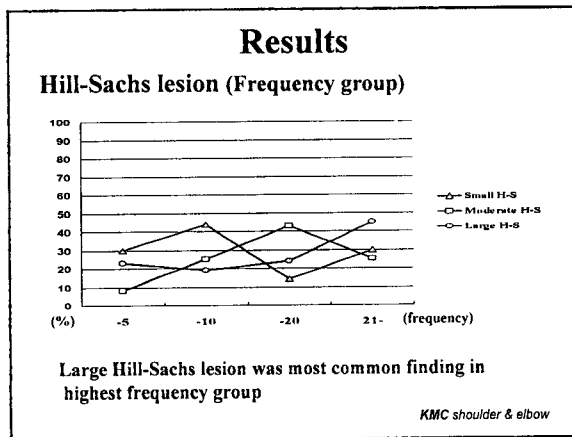
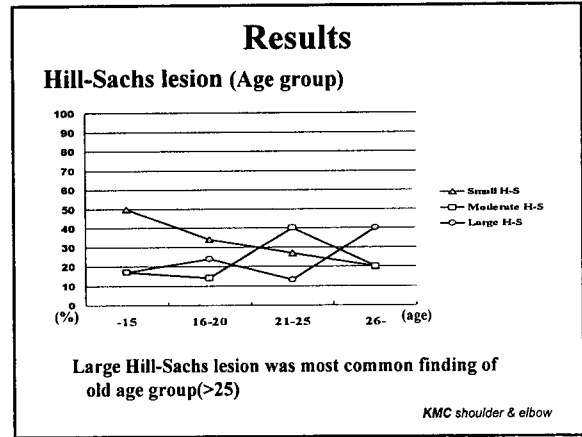
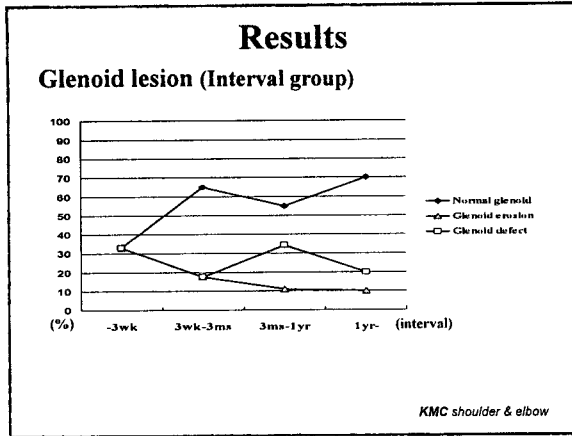
Results

Operative findings (Interval group)

	-3wk	3wk-3ms	3ms-1yr	1yr-
Classic Bankart	9	24	20	16
Midsubstance tear	3	5	6	2
ALPSA	2	2	4	1
HAGL	2	2	1	
Bony Bankart	6	9	5	1

KMC shoulder & elbow





Summary

SECOND TIME DISLOCATION

- Conservative treatment
- Operation
 - late teens
 - early episode of redislocation
 - non-classic Bankart lesion

KMC shoulder & elbow