

Posterior Instability of the Shoulder

by
Richard J. Hawkins, M.D., FRCS(c)
for

2002 ACASA
Nov. 2, 2002
Seoul, Korea 2002

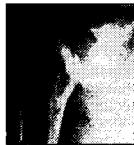

Classification, Evaluation & Surgical Treatment with Infraspinatus Tenodesis



Classification Post INS

- Locked posterior dislocation
- Recurrent posterior subluxation (unidirectional)
- Recurrent posterior instability -- MDI



Classification Recurrent Posterior Subluxation (unidirectional)

- Voluntary
 - Habitual (psychological)
 - Not
 - Muscle contracture
- Involuntary
 - Arm positioning
 - Patient demonstration
 - With activities



MDI with Posterior Component

- Post subluxation (symptomatic)
- Inferior subluxation (symptomatic)
- Increased anterior translation



Locked Posterior Dislocation

- | | |
|--------------------------|--------------------------|
| Acute | Acute |
| • <20% defect | • >20-40% defect |
| • Reduce | • Subscapularis Transfer |
| • Temporarily immobilize | |



Locked Posterior Dislocation

Chronic

- 20-40% defect
- < 1year
- Subscapularis Transfer

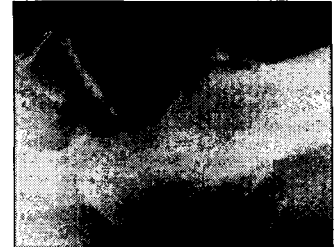Chronic

- > 50%
- Hemi-arthroplasty

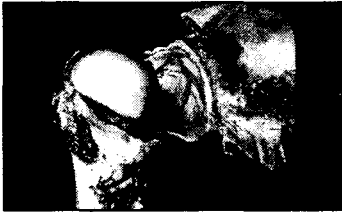Locked Posterior Dislocation

Chronic

- > 50%
- >1 year
- Hemi-arthroplasty



STABILITY - LIGAMENTS



TURKEL et al.
JBJS 1981

Translation Testing

“Load Shift”

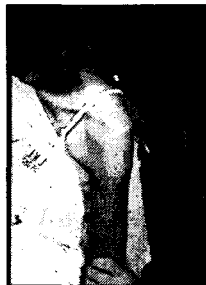“Sulcus Sign”

ANT-POST
Drawer

INF Drawer

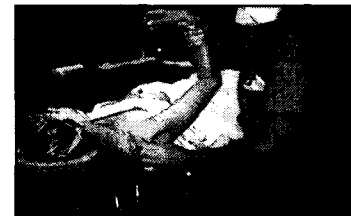SYMPTOMATIC TRANSLATION

- Posterior
- Anterior
- Inferior



EUA

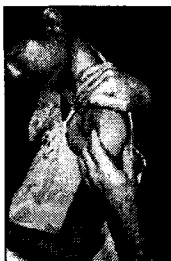- Anterior
- Inferior
- Posterior



Translation

Evaluation

- Not as straightforward as anterior instability
- Careful history
- P/E
- Insidious onset
- Often more annoying than disabling



Evaluation

- Confusing pathologic conditions
- Classifying
- Interpreting P/E
- Conservative treatment
- Operative intervention

Diagnosis Video

RECURRENT POSTERIOR SUBLUXATION

Treatment mostly
nonoperative,
aggressive
rehabilitation

Surgical Options

- Soft tissue procedures
 - Reverse Putti Platt
 - Boyd & Sisk transfer
 - Inferior capsular shift (with MDI)

Surgical Options

- Glenoid osteotomy
 - Technique
 - Complications
- Bone grafting
 - Application
 - Technique

Essadki B, et al. Rev Chir Orthop Reparatrice Mot. 2002, Dec ;86
Gosens T, et al. Acta Orthop Belg. 2001, Apr;67

For Open Posterior instability

**Posterior Infrapinatus Tenodesis
Capsular Repair
to Glenoid Labrum**

**Preferred Method of Treatment
Must
Rule Out MDI**

Posterior Capsulorrhaphy

RESULTS

- 14 athletes (3 were throwers) with traumatic, uni-dir posterior INS
- 45 month f/u on 14
- 1 recurrence of posterior instability treated surgically
- 13/14 reported good to excellent results

Misamore GW, Facibene WA; JSES 2000

Inf Tenodesis Results

- 17 patients
- 44 month f/u on 14
- No recurrence of posterior instability
- 13/14 satisfied with outcomes

Category	pre-op	post-op
Pain	5	2
ADL Pain	9	4

Hawkins RJ, Janda DH; AJSM 1996

**Recent Advances
Treatment of Posterior Instability**

Author	N	Heat	Plicate	Failure
Hawk	9	Laser	No	0%
Hawk	19	RF	No	22%
Abrams	25	RF	ALL	8%

Current Open Results

- 2yr f/u on 20/22 patients 95-2000
- 3/20 (15%) Failure rate
 - 2/20 (10%) 2nd Instability procedure
 - 1/20 (5%) too tight released
- 17 success
 - ASES pre-op = 55.9
 - ASES post-op = 82.9

Laser Results

- 2yr f/u on 9/9 patients
- (1/9 failed – too tight, now doing fine)
- 8 Stable and satisfied
 - ASES pre-op = 67.8
 - ASES post-op = 93.8

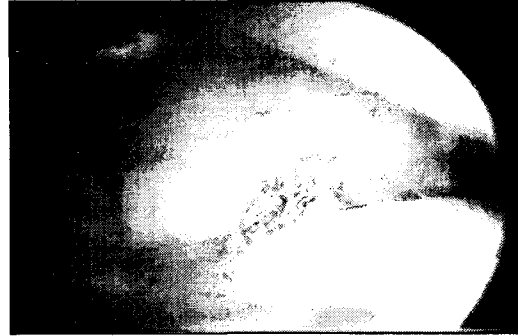
accepted Arthroscopy

Reported Common Theme

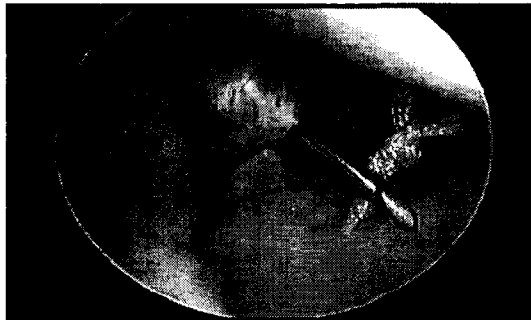Capsular plication and interval closure appear to improve success rates...

For Posterior & MDI

Capsular Plication



Rotator Interval Closure for POST



Present Approach

Open if:

- 1. Second time i.e. (failure)**
- 2. Close rotator interval open or arthroscopic**
- 3. Immobilization 6 weeks**

Present Approach

If MDI

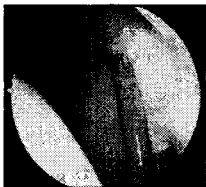- 1. Post – plicate & heat**
- 2. Ant/ Inf – open shift & close interval**

References

1. Fronek J, Pavlov BH, Warren R: Posterior subluxation of the glenohumeral joint. Nonsurgical & surgical treatment. Orthop. Trans., vol 20. (2) p220.
2. Hawkins RJ, Koppert G, Johnston G. Recurrent posterior instability (subluxation) of the shoulder. JBJS Am 1984 Feb;66(2):169-74.
3. Johnson HG, Hawkins RJ, Fowler PJ, Haddad RA: Complication of Posterior Glenoid Osteotomy for Recurrent Posterior Shoulder. Clinical Orth 187; 1984. 147-.
4. GHawkins RJ, Neer CS 2nd, Pianta RM, Mendoza FX. Locked posterior dislocation of the shoulder. JBJS (Am) 1987 Jan;69(1):9-18
5. Neer CS, II, Foster CR: Inferior capsular shift for involuntary inferior and multidirectional instability of the shoulder. A preliminary report. JBJS(Am) 1980 Sep;62(6):897-908.
6. Essadki B, Dumontier C, Sautet A, Apoll A. Posterior shoulder instability in athletes: surgical treatment with iliac bone block. Apropos of 6 case reports. Rev Chir Orthop Reparatrice Appar Mot 2000 Dec;86(6):765-72.
7. Gosens T, van Biezen FC, Verhaar JA. The bone block procedure in recurrent posterior shoulder instability. Acta Orthop Belg 2001 Apr;67(2):116-20.
8. Hawkins RJ, Janda D. Posterior instability of the glenohumeral joint. A technique of repair. AJSM 1996 May-Jun;24(3):275-8.
9. Tibone JE, Bradley JP. The treatment of posterior subluxation in athletes. Clin Orthop 1993 Jun;(291):124-37
10. Misamore GW, Facibene WA. Posterior capsulorrhaphy for the treatment of traumatic recurrent posterior subluxations of the shoulder in athletes. JSES. 2000;9(5):403-8.

ETAC Results

- 2yr f/u on 13/20 patients
 - 3/13 (23%) Failure - 2nd Instability procedure
- 10 Stable and satisfied
 - ASES pre-op = 70.0
 - ASES post-op = 87.0



IMMOBILAZITION

Was Short

IMMOBILAZITION

T. Schlegel

Basic Science

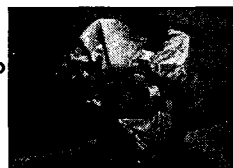- Rabbit Patellar Tendon
- Immobilization
- Maintained Contracture



Presented at AOSSM 1999

Rehabilitation Following Posterior Repair

- Immobilization
 - Upper arm slightly posterior to coronal plane
 - Forearm externally rotated 20° for 6 weeks
 - Strengthening within limited range initially
 - Rehab 6 to 12 months
 - Less emphasis on stretching due to tendency of posterior instability patients toward MDI



4wk traumatic
6wk atraumatic

Posterior Patient Satisfaction

- Patient satisfaction (PS)
 - Failures were defined by a satisfaction grade of less than 5 & ASES score <80, indicating pain & decreased function
 - XX/XX (XX%) patients had revisions
 - XX/XX (XX %) failed by PS criteria
 - Combined failures 24/105 (22.3%)

Recurrent Posterior Instability

Have many episodes of instability ...

But score high

